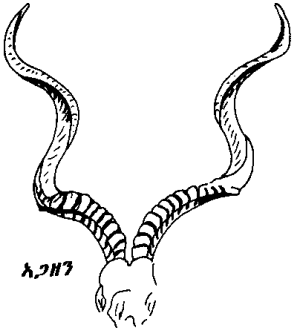
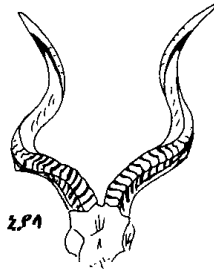


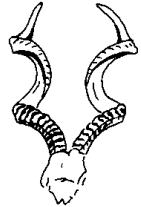የጌር እንስሳት ቀንድ



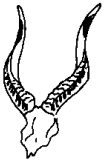አጋዘን



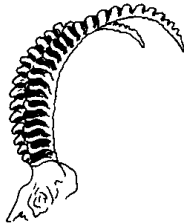
ኒያላ



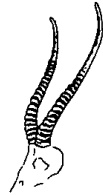አምባራይሌ



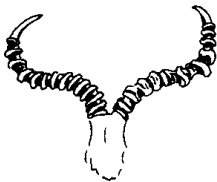
ምኒልክ ድኩላ



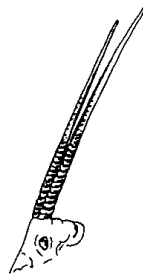
ጥልያ



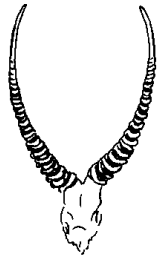
ግዳ ፍጥራ



ቆርኬ



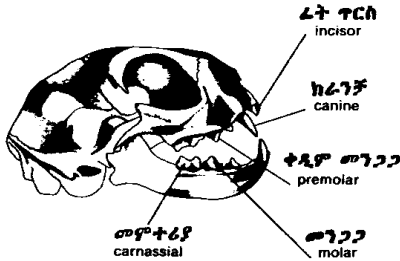
ሳላ



ድፋርሳ

የግንባራ አይነቶች
types of jaws

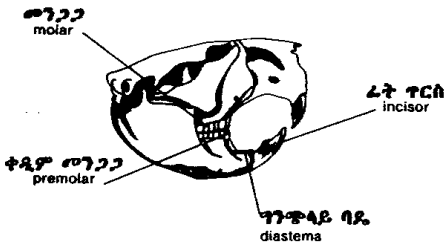
ስጋበላ ግንባራ(ፆ)
carnivore's jaw



ነብር
leopard



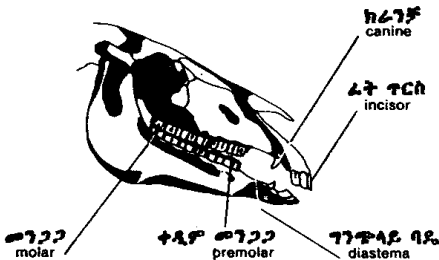
አይጥላስተኔ ግንባራ
rodent's jaw



ቢቩር
beaver

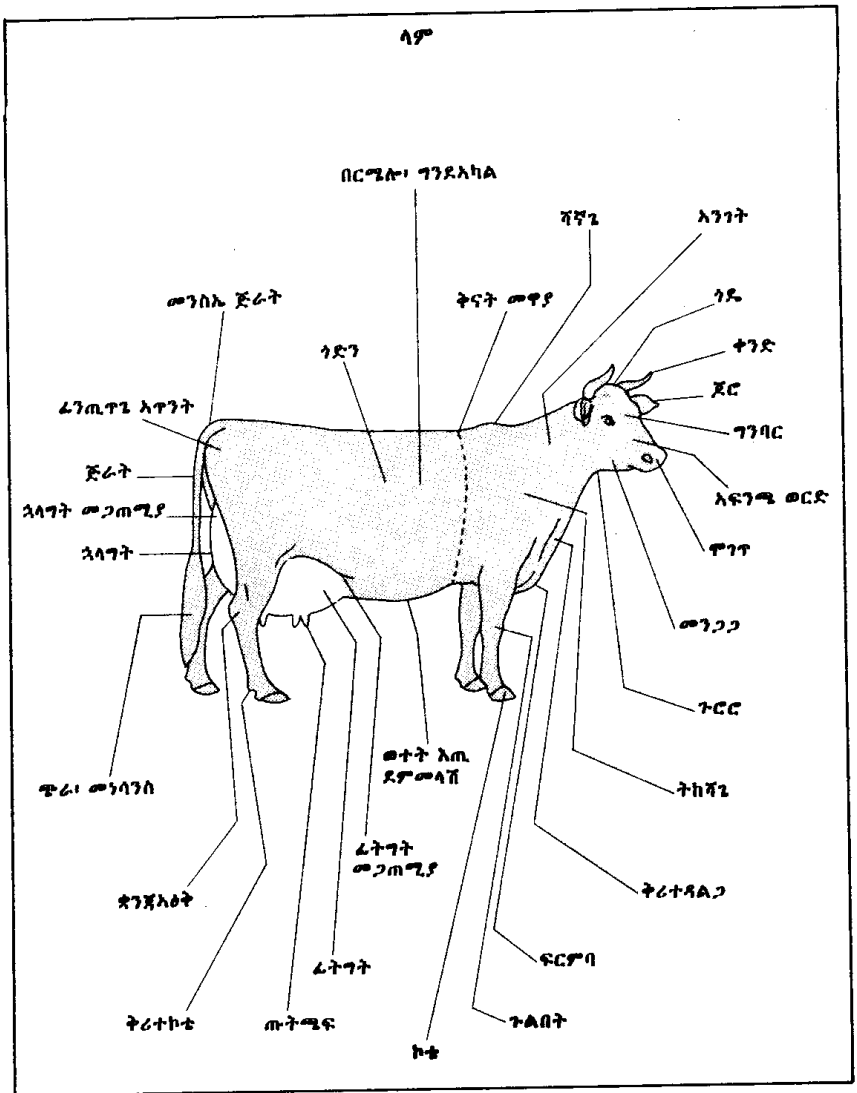


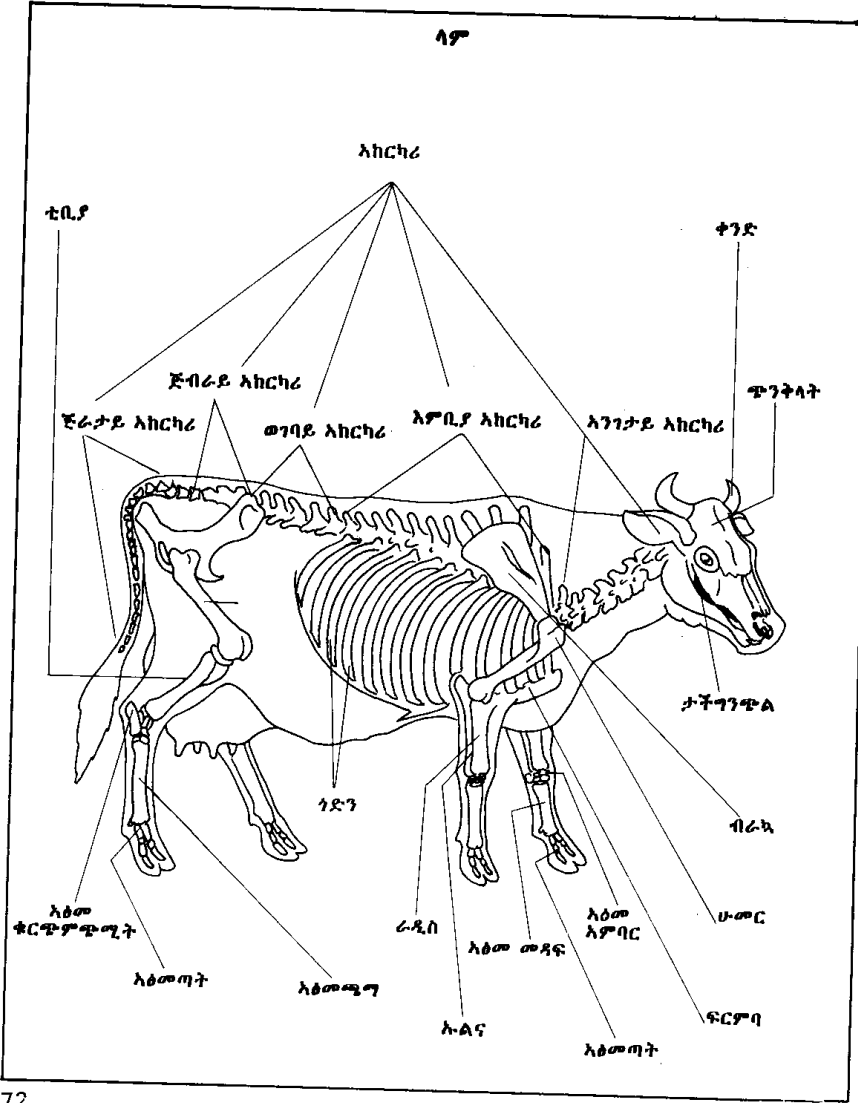
እፅዋትበላ ግንባራ
herbivore's jaw

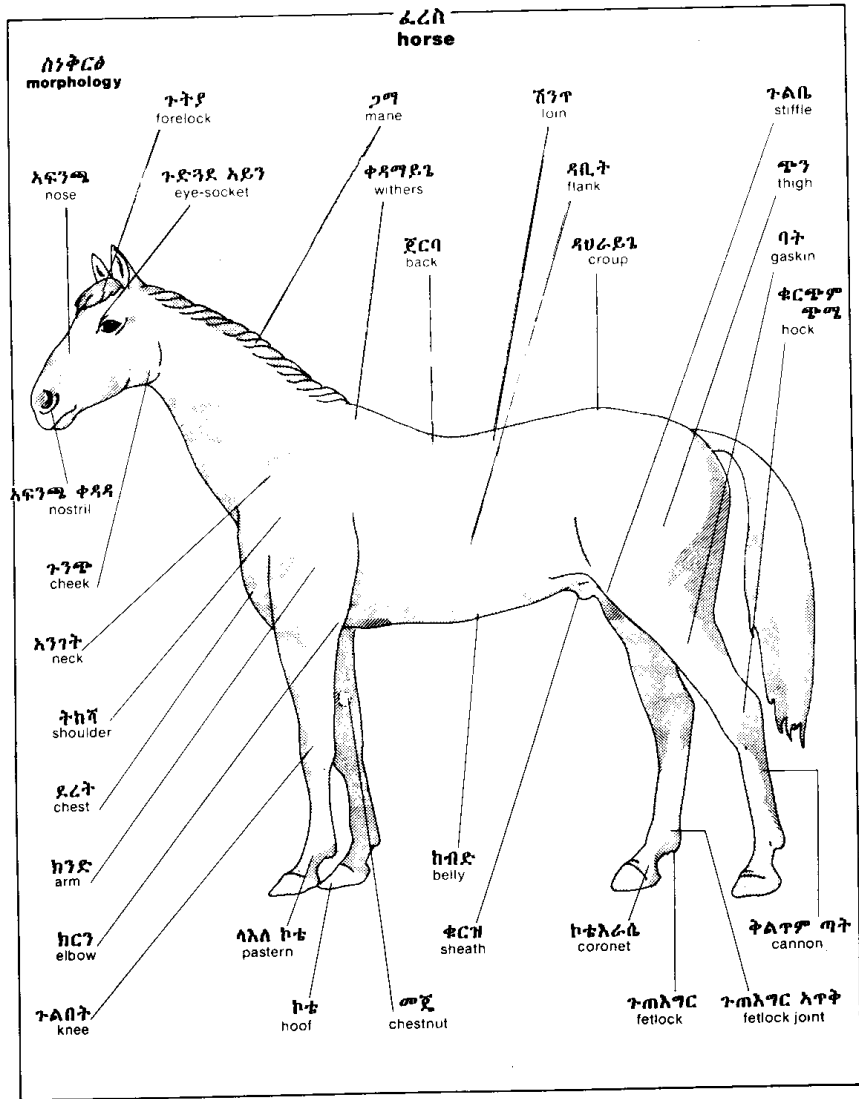


ፈረስ
horse









ፈረስ
horse

እፅዎ
skeleton

ታችኛው ግንጭል
mandible

አንገት አከርካሪ
cervical vertebrae

እምቤ አከርካሪ
thoracic vertebrae

ወገባይ አከርካሪ
lumbar vertebrae

ራስ ቅል
skull

ጅብራይ አከርካሪ
sacral vertebrae

ጅራታይ አከርካሪ
caudal vertebrae

ብራህ
scapula

ሁመር
humerus

ፍርንባ
sternum

ራዲስ
radius

ገድገ
ribs

ፈሙር
femur

ጉልበት ሎጊ
patella

እንባር እጥዎ
carpus

ዳሌ እጥንት
pelvis

መዳፍ እጥዎ
metacarpus

ቲቢያ
tibia

እፅመጣት
phalange

ታርሶስ
tarsus

እፅመ ተረከዝ
calcaneus

ርሁት ጉንቁሌ
distal sesamoid

ቀረብ ጉንቁሌ
proximal sesamoid

እጥመ ሚግ
metatarsus

ድመት
cat

እራስ
head

ላይኛ እይን ቶብ
upper eyelid

ጨንጭረ ክርታስ
nictitating membrane

ታችኛ እይን ቶብ
lower eyelid

እፍንጫ ቱርበት
nose leather


ጢዎ
whiskers

ቅንድብ
eyelashes

ብሌን
pupil

ጥገጥ
muzzle

ከንፈር
lip



ፈት እግር
foreleg

ስብስብ ግንርጥ
retracted claw

እጥባራይ መደላድል
carpal pad

ቅሪት መደላድል
dew pad

ቅሪት ግንርጥ
dew claw

መዳፋይ መደላድል
palmar pad

ጣታይ መደላድል
digital pad

ግንርጥ
claw

ግንርጥ
claw

ርሁት እፅመጣት
distal phalanx

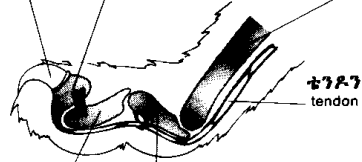
መዳፍ አጥዎ
metacarpus

ቴንዶን
tendon

መሃል እፅመጣት
middle phalanx

ቀሪብ እፅመጣት
proximal phalanx

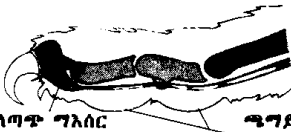
ዘርግ ግንርጥ
extended claw

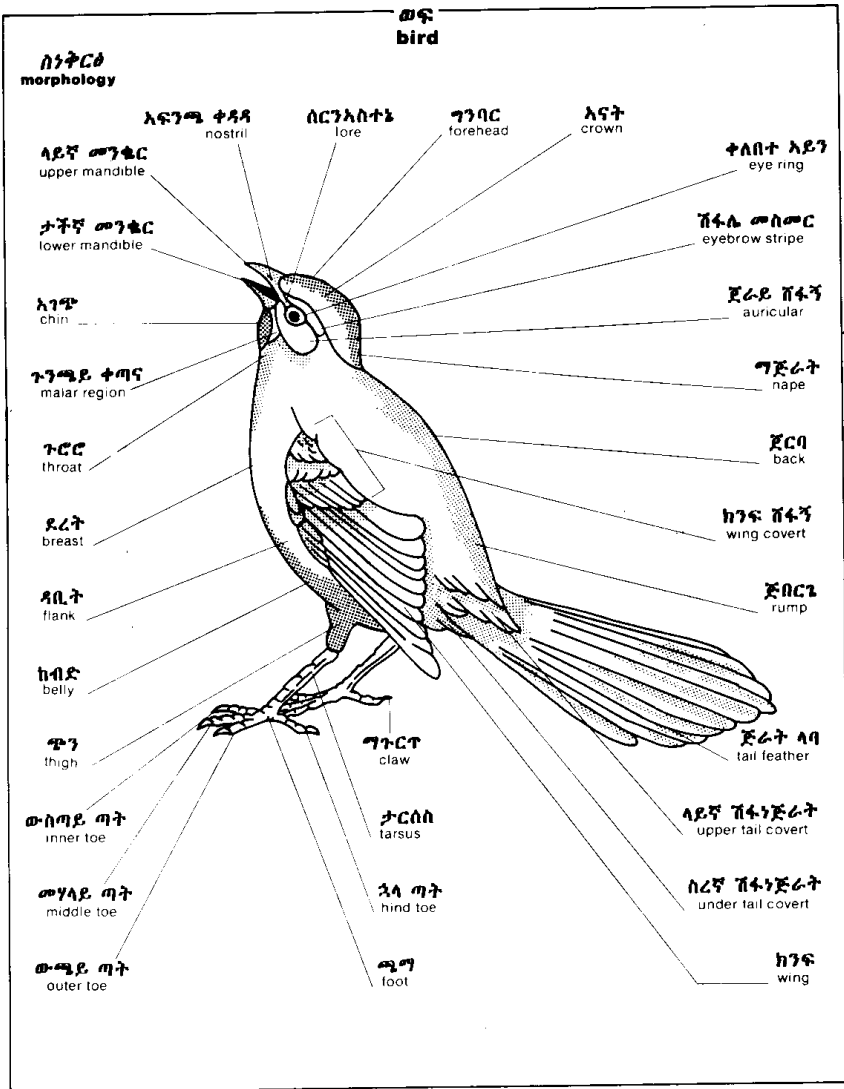


ጣት
digit

ተለጣጥ ግእሰር
elastic ligament

ጫግይ መደላድል
plantar pad





ወፍ
bird

ሰነትርቆ
morphology

እፍንጫ ቀዳዳ
nostril

ሰርንአስተኔ
lore

ግንባር
forehead

አናት
crown

ቀለበተ አይን
eye ring

ላይኛ መንፎር
upper mandible

ታችኛ መንፎር
lower mandible

አገጭ
chin

ጉንጫይ ቀጣና
malar region

ጉርር
throat

ደረት
breast

ላቢት
flank

ከብድ
belly

ጭን
thigh

ውስጣይ ጣት
inner toe

መካላይ ጣት
middle toe

ውጫይ ጣት
outer toe

ግጉርጉ
claw

ታርሰስ
tarsus

ኋላ ጣት
hind toe

ጫጣ
foot

ሽፋሌ መስመር
eyebrow stripe

ጀራይ ሸፋኝ
auricular

ግጅራት
nape

ጀርባ
back

ከንፍ ሸፋኝ
wing covert

ጅቦርጌ
rump

ጅራት ላባ
tail feather

ላይኛ ሸፋኝጅራት
upper tail covert

ሰርኛ ሸፋኝጅራት
under tail covert

ከንፍ
wing

ወፍ
bird

ክንፍ
wing

ንኡስ ሸፋኝ
lesser covert

መለሰተኛ ሸፋኝ
middle covert

አቢይ ሸፍፍ
greater covert

ብራካይ
scapular

tertial
ሶስተኛ ደረጃ ላባ

ሁለተኛ ደረጃ ላባ
secondaries

ቀዳማይ ሸፋኝ
primary covert

ጣት ላባ
alula

መሃላይ ቀዳማይ ሸፋኝ
middle primary covert

እንደኛ ደረጃ ላባ
primaries

ቅርፅ ላባ
contour feather

ላባ ዘንግ
rachis

ላይኛ ብስ
superior umbilicus

ላባ ብር
calamus

ታችኛ ብስ
inferior umbilicus

ዘርፈ ላባ
barb

ክፍለ ላባ
vane

እንግዶ ላባ
afterfeather

ወፍ
bird

ዋና ዋና የመንቆር አይነቶች
principal types of bills



ውሂ ወፍ
aquatic bird



አዳኝ ወፍ
bird of prey



ጠንካሻበል ወፍ
insectivorous bird



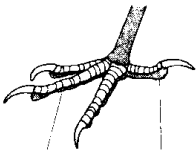
አዝርእትበል ወፍ
granivorous bird



ተንቦሜርቂ ወፍ
wading bird

ዋና ዋና የሚጣ አይነቶች
principal types of feet

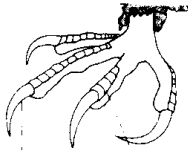
ሰፋሪ ወፍ
perching bird



ቀዳማይ ጣት
toe

ኋላ ጣት
hind toe

አዳኝ ወፍ
bird of prey



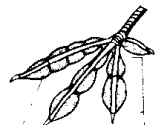ጣጉርጥ
claw

ቅርፊት
scale

ውሂ ወፍ
aquatic bird



ጃንጥሌ
web



ዞፈፍ
lobe

ዞፈፍ ደ ጃንጥሌ
lobate web

እንቁላል
egg

ነጫ እንቁላል
albumen

አሰኳል
yolk

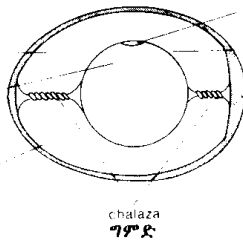
ክርታሰ ቅርፊት
shell membrane

መግሊተ ፅንሰ
blastodisc

ክርታሰ አሰኳል
vitelline membrane

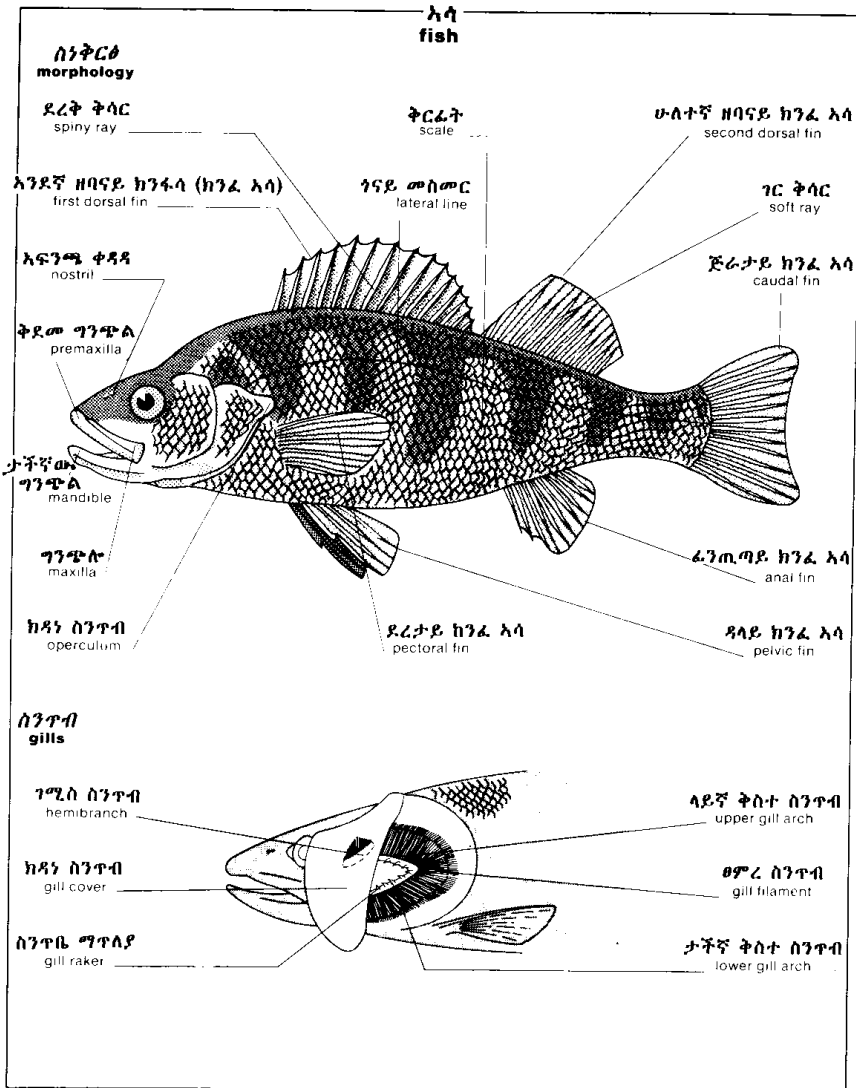
አየር ቋት
air space

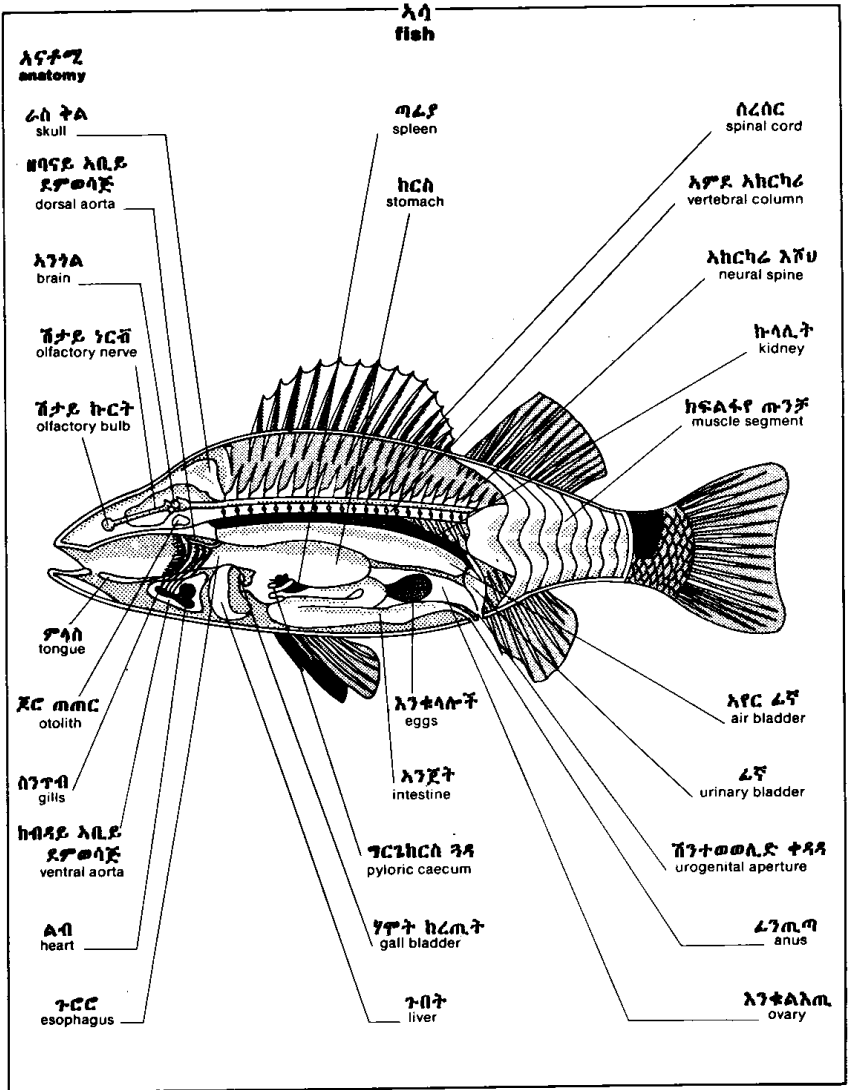
ቅርፊት
shell

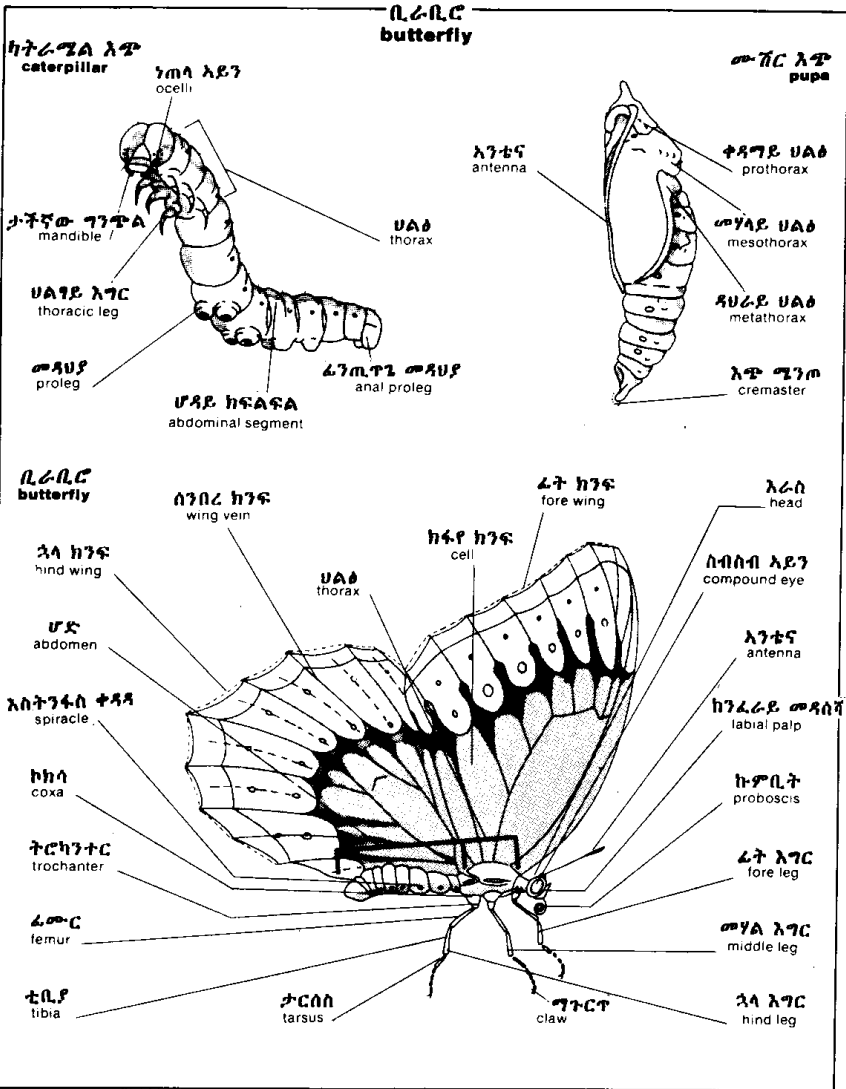


ታሊላ
chalaza

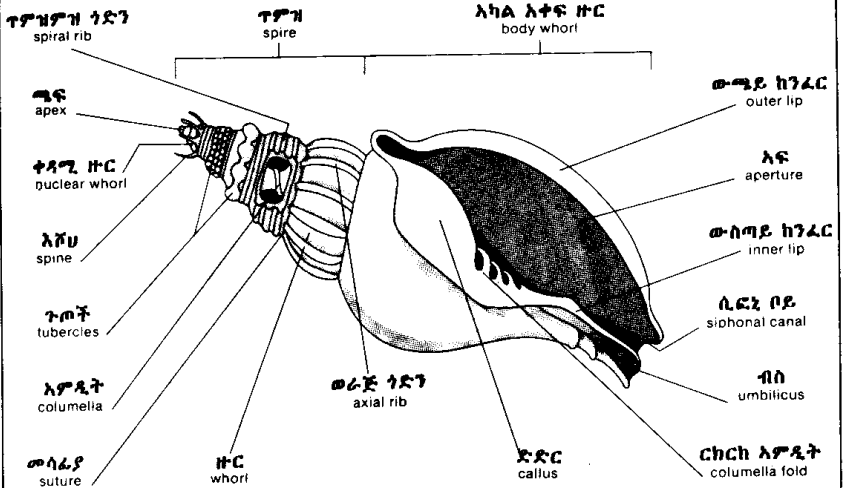
ግምድ





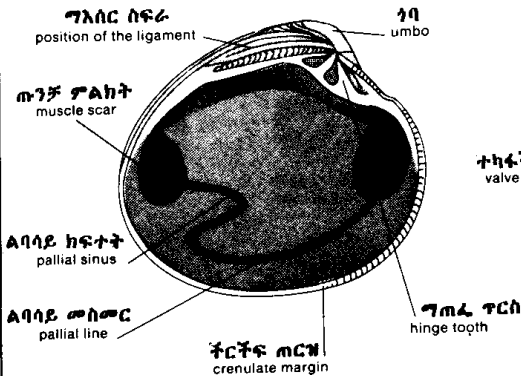


እንድወጤ ዛጎል
univalve shell

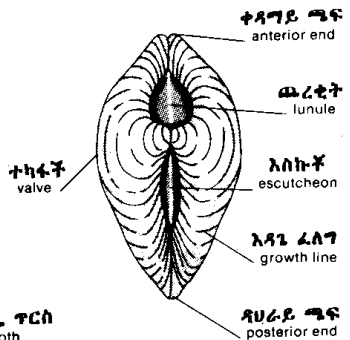


ክልኤተካፋች ዛጎል
bivalve shell

ገራ ተካፋች
left valve

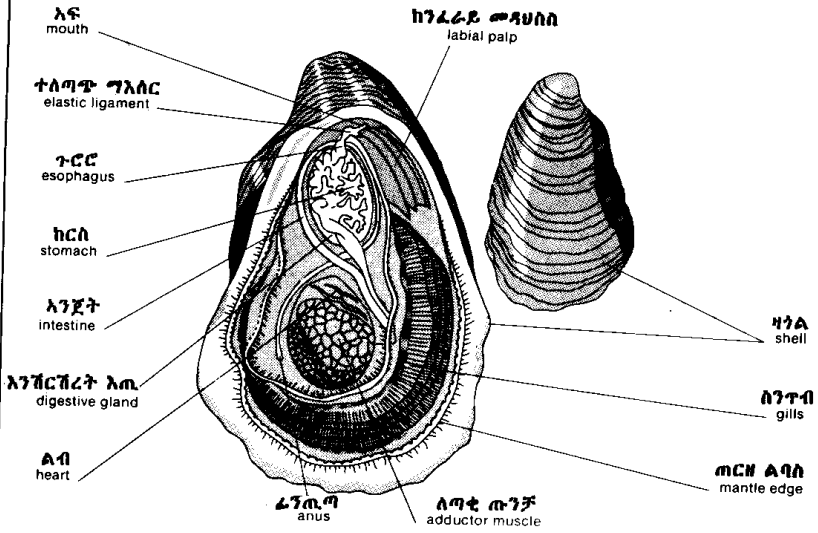


ዘባናይ ገፅ
dorsal view



ጥላስክ
mollusk

አይስተር
oyster



ጥና ጥና የሚበሉ ጥላስኮች
principal edible mollusks

ካጎለጥንከር ክላም
hard shell clam



ካጎለገር ክላም
soft shell clam



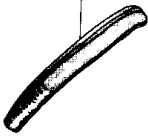
ብክላ
cockle



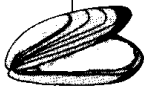ክላም
clam



ጥላጭ ክላም
razor clam




ትልት ስካሉፕ
blue mussel



ትላት ስካሉፕ
great scallop

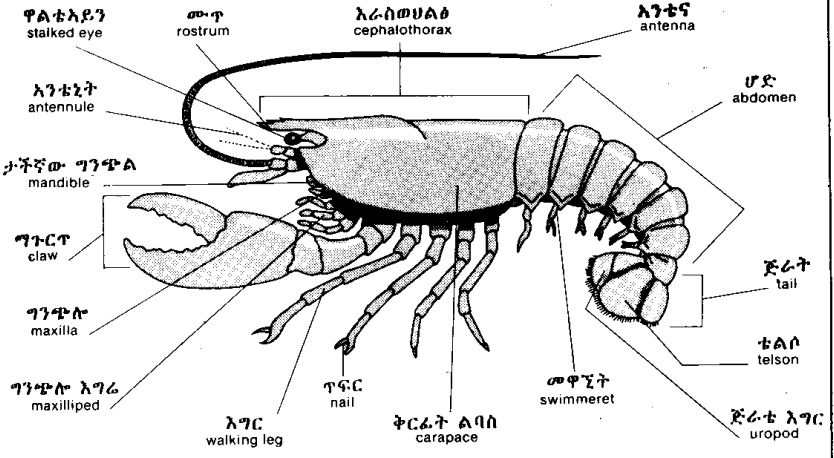


ስካሉፕ
scallop

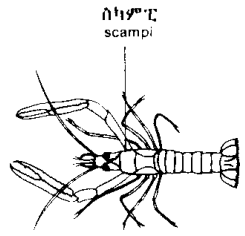
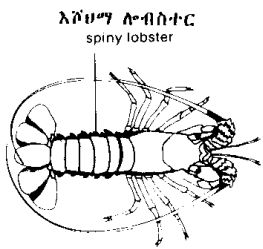
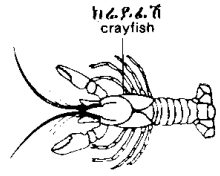
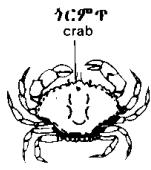
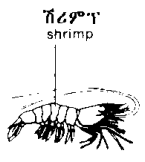


ክራስቲሻ
crustacean

ሎብስተር
lobster

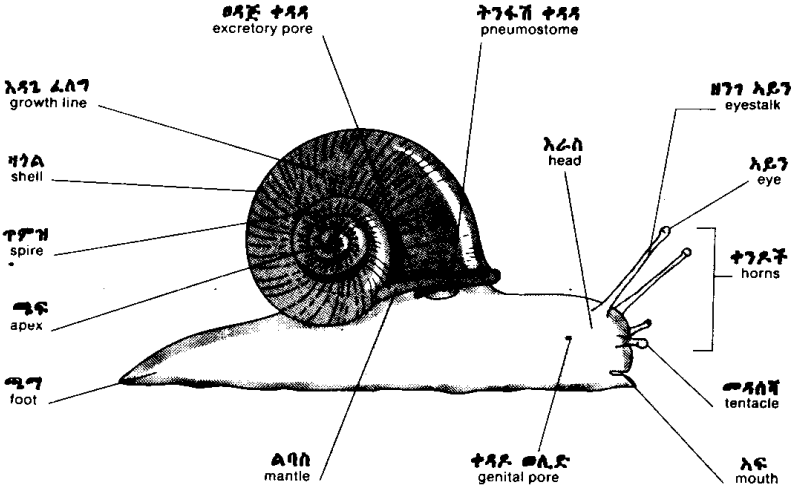


ዋና ዋና የሚበሉ ክራስቲሻዎች
principal edible crustaceans

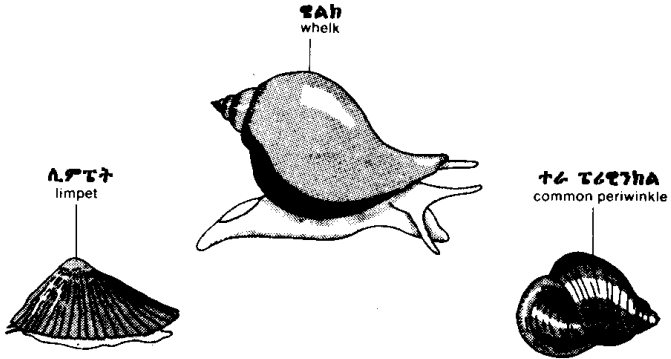


ጋስትሮፖድ
gastropod

ተንድአውጣ (ተንዳውጣ)
snail



ዋና ዋና የሚበሉ ጋስትሮፖዶች
principal edible gastropods



ባትራኪያን
batrachian

እንጭራሪት
frog

ወሴ አፍንጫ
snout

አይነኳስ
eyeball

ላይኛ አይን ቀብ
upper eyelid

አፍንጫ ቀዳዳ
naris

ከርታስ ጆሮ
tympanum

ቆዳ
skin

ታችኛ አይን ቀብ
lower eyelid

ኋላ እግር
hind limb

አፍ
mouth

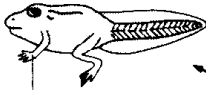
ጣት
digit

ፊት እግር
forelimb

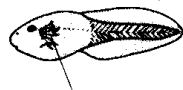
ጃንጥሌ ጣት
webbed toe

እንጭራሪት
eggs

እንጭራሪት ሎዲተሪዮስ (የ)
life cycle of the frog



ፊት እግር
forelimb



ውጫይ ስንጥቦች
external gills

ከዳነ ስንጥብ
operculum

ኋላ እግር
hind limb

ኋላ እግር አፅዋ
skeleton of the hindlimb

አምደ አከርካሪ
vertebral column

ዳላይ ጫንብሌ እግር
pelvic girdle

ጆሮ አጥንት
urostyle

ቲቢያውራቢላ
tibiolfibula

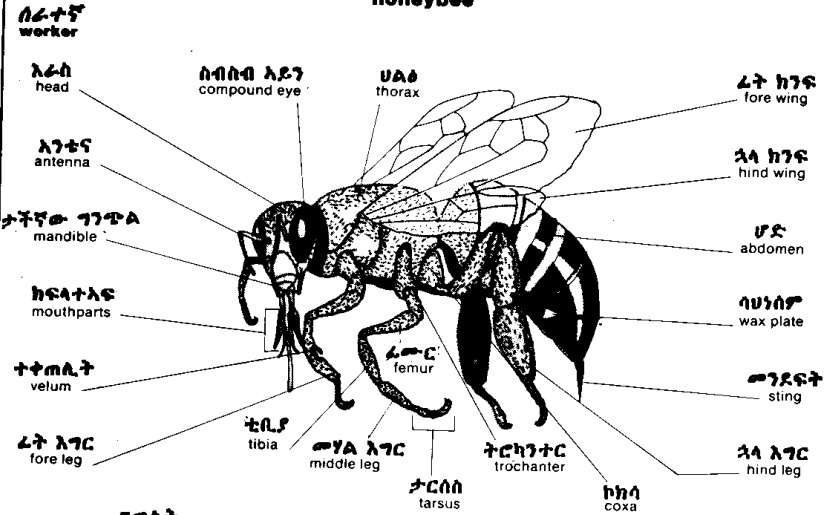
ፊሙር
femur

ታርሱስ
tarsus

አፅግተ ጣት
phalanxes

አጥሎ ጫግ
metatarsus

ግርግሳ
honeybee



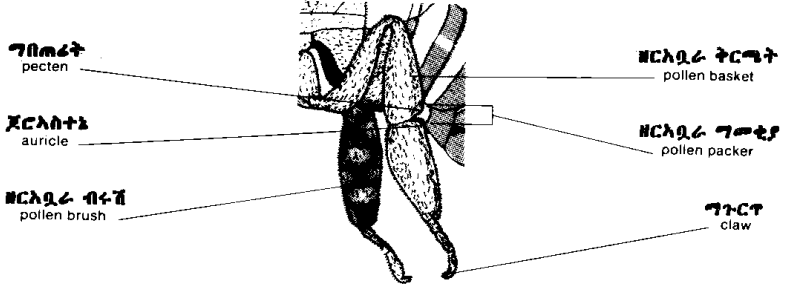
ግግስት
queen



ድንጉላ
drone



የሰራተኛ ግሳ የጳላ እግሮች
hind legs of the worker



ግርግብ
honeybee

ቀር
hive

እየር ቀላላ
air hole

ክፈፍ (ጠርዝ)
frame

ንግስት ግግላያ
queen excluder

መቀቀፊያ ክፍል
brood chamber

መግቢያ
entrance

ግረረያ ሳንታ
alighting board

ግርግብ ክፍል
honeycomb section

መፈለፊያ እንቁራ
brood cell

እጭ
larva

እንቁላ
egg

ክርእባራ እንቁራ
pollen cell

ጣሬያ
roof

ግርግብ መሰረት
comb foundation

ግርግብ ፍራፍ
super

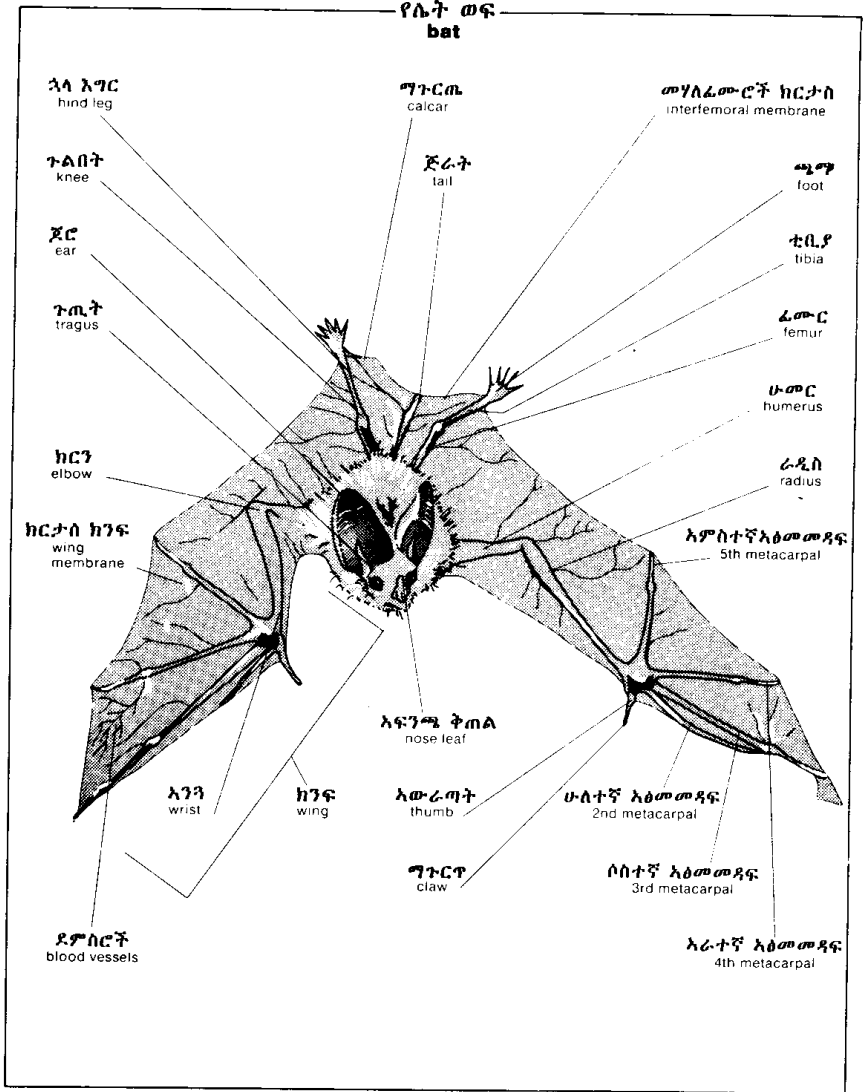
ቀር እካል
hive body

ተንሸራታት መዝጊያ
entrance slide

እሸግ እንቁራ
sealed cell

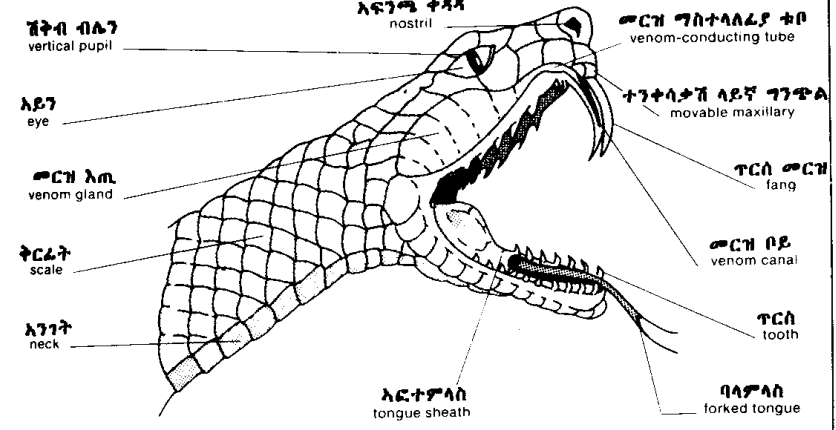
ግር እንቁራ
honey cell

ንግስት እንቁራ
queen cell

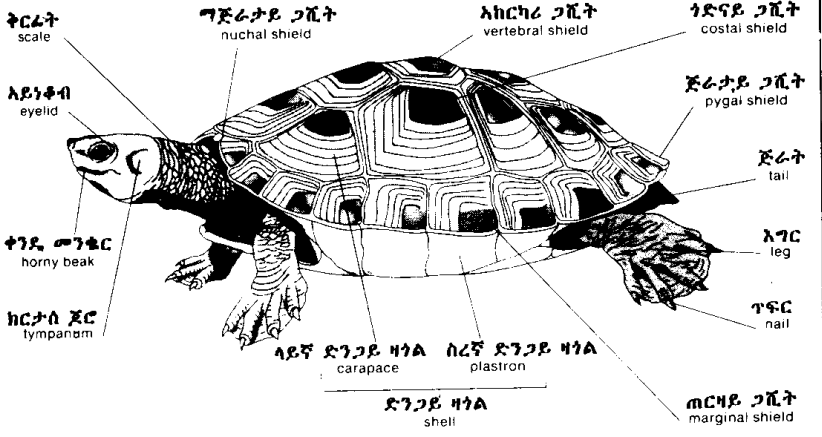


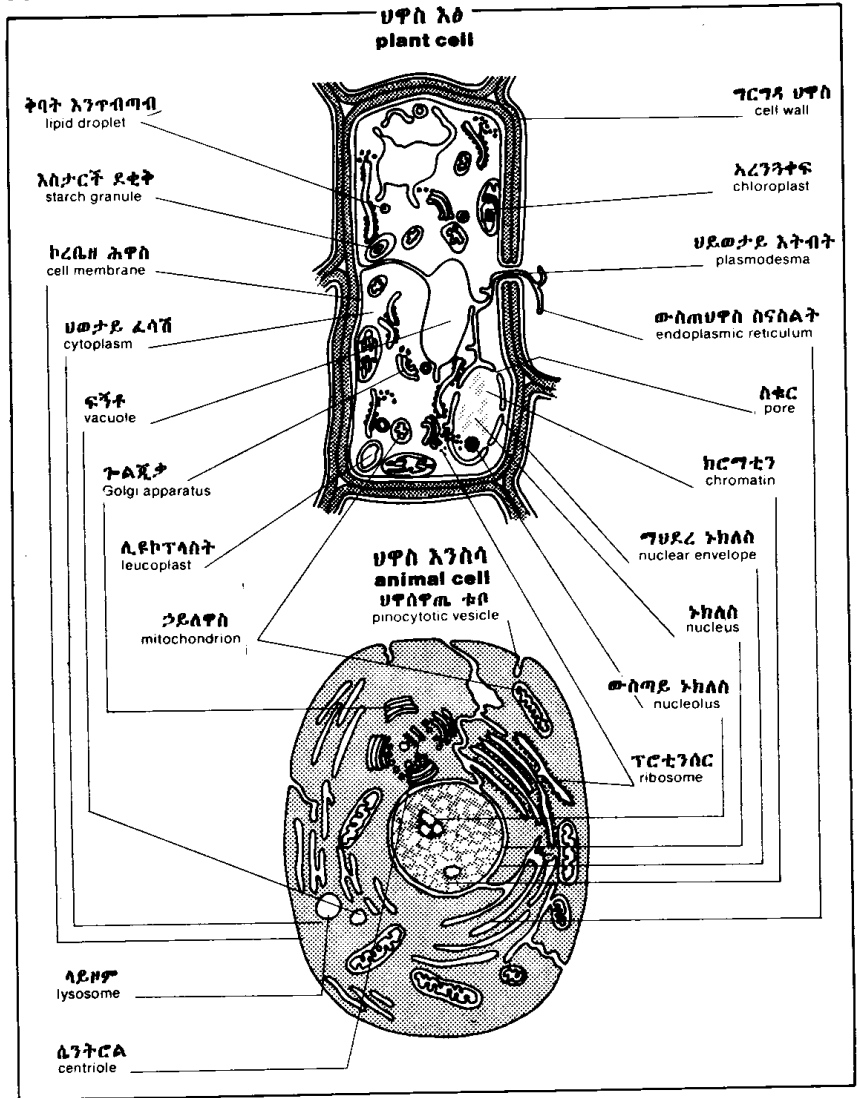
ሬፕቲል
reptile

የመርከኛ እባብ ጭንቅላት
venomous snake's head



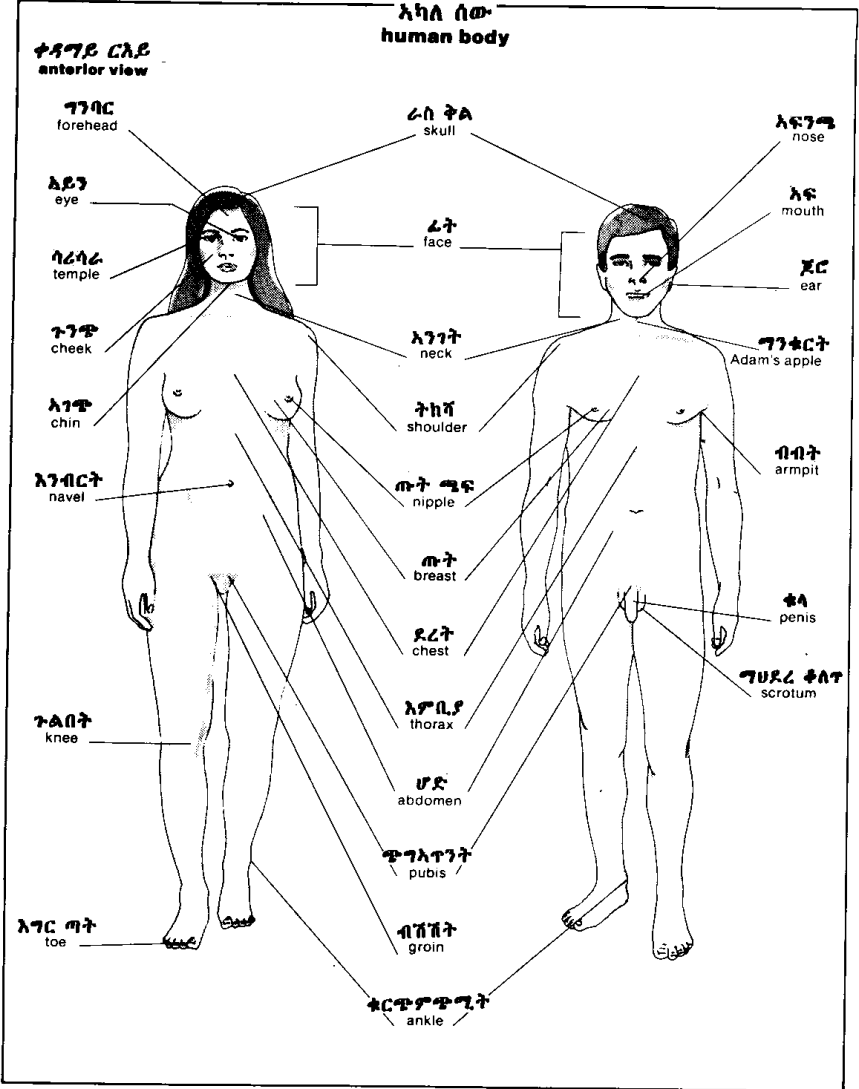
ሌሊ
turtle





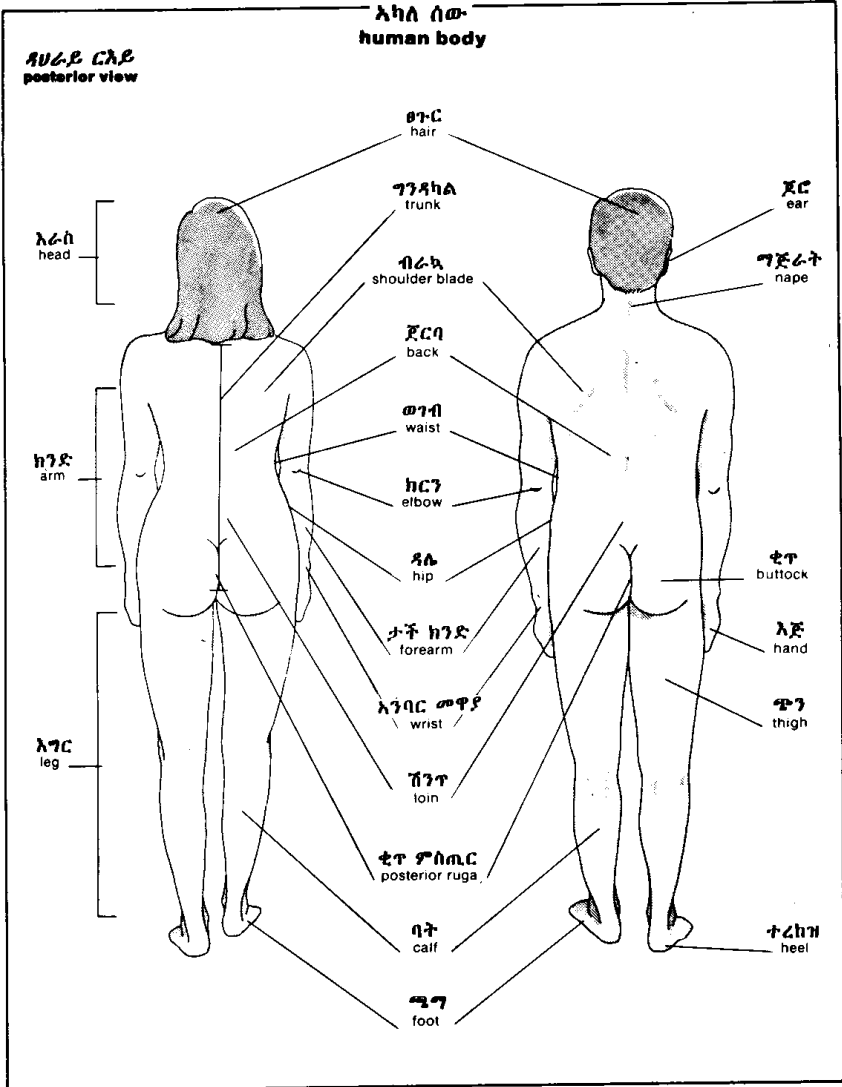
እካለ ሰው
human body

ቀዳግይ ርእይ
anterior view



እካል ሰው
human body

ጸሀራይ ርእይ
posterior view



የወንድ አባላተወሊድ
genital organs
male

ፍሉጥ አካል
sagittal section
ከባቢሆድታ ክርታስ
peritoneum

ፊኛ
urinary bladder

ፐሮስቲት ለጢ
prostate

ጋጥሮ ጭገላጥንት
symphysis pubis

ጥሻግ አካል
cavernous body

የወንድ ቦዩሽንት
male urethra

ቱላ
penis

ላፕሱፕ
prepuce

ቱላራስ
glans penis

ሽንት ተጻፋ
urinary meatus

ግህደረ ቀለጥ
scrotum

ቀለጥ
testicle

ወሳደ ቦይ
deferent duct

እረብ
rectum

ፍሰሊጢ
seminal vesicle

ጢቅታ ቦይ
ejaculatory duct

ካውፐር ለጢ
Cowper's gland

ፈንጢጣ
anus

ሰፍንጊ አካል
spongy body

አንጠልጥን ቀለጥ
septum of scrotum

ግህደረ ቀለጥ ከፋሲ
spermatic cord

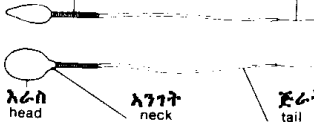ወንድ ዘር
spermatozoon

ጎናይ ርእይ
side view

ዘርግ እይታ
flat view

መካከለኛ አካል
middle piece

ግፍአካል
end piece



አራስ
head

አንገት
neck

ጅራት
tail

የሴት አባባተወሊድ
genital organs
female

ፍላጥ አካል
sagittal section

እንቁላጢ
ovary

ፊኛ
urinary bladder

ጋጥሞ ጭገአጥንት
symphysis pubis

ዲባጭጥኝ
mons pubis

ቦዩሽንት
urethra

ቲንጥር
clitoris

ውጭኛ
እምስ
vulva

ንኡስ ከንገረ
lesser lip

አቢይ ከንገረ
greater lip

ግሀፀን ቱቦ
uterine tube

ግሀፀን
uterus

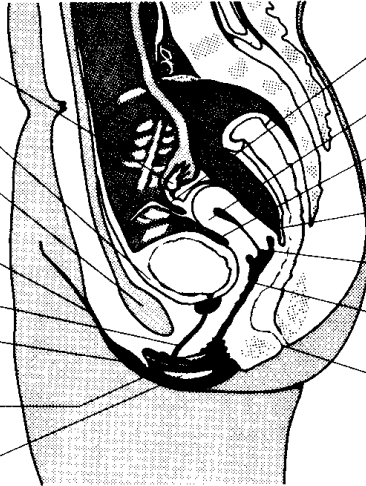
ፊኛ ግሀፀን ከረጢት
uterovesical pouch

ዳግላስ ከረጢት
pouch of Douglas

አንገተ ግሀፀን
neck of uterus

እምስ
vagina

ፈንጢጣ
anus



ቀዳገይ ርእይ
anterior view

ግሀፀን ቱቦ
uterine tube

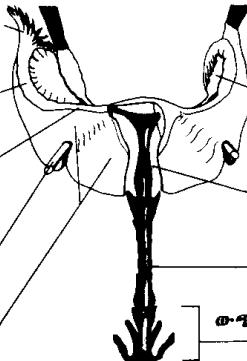
ግሀፀን ቱቦ ላፍ
infundibulum of uterine tube

ግሀፀን ቱቦ ለቡጥ
ampulla of uterine tube

ግሀፀን ቱቦ ጥቡብ
isthmus of uterine tube

ከብ ግእሰረ ግሀፀን
round ligament of uterus

ዝርግ ግእሰረ ግሀፀን
broad ligament of uterus



እንቁላ
እጢ
ovary

ግሀፀን
uterus

እምስ
vagina

ውጭኛ እምስ
vulva

የጡት ፍላጥ አካል
breast
sagittal section

ወተት እጢ
mammary gland

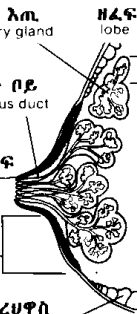
ወተት ቦይ
lactiferous duct

ጡት ጫፍ
nipple

ድባብ ጡት
areola

ስብ ሀብረሀዋስ
adipose tissue

ዘረፍ
lobe



ጠንቅቶች
muscles

ገንባራዊ ጠንቅቶች
frontal

ቀዳማዊ ርእይ
anterior view

አኛኪ ጠንቅቶች
masseter

ሶስት ግእዘኔ ጠንቅቶች
deltoid

ውጫይ ሰያፍ ጠንቅቶች
external oblique

ቀጢ ሆዳይ ጠንቅቶች
abdominal rectus

ላይክንዶ ወራዲስ ጠንቅቶች
brachioradial

ወጣሬ ሰፊ ፍሻ
tensor of fascia lata

ረጅሚ ለጣቂ ጠንቅቶች
long adductor

ሰፊ ጠንቅቶች
sartorius

ቀጢ የጭን ጠንቅቶች
straight muscle of thigh

ጎናይ ትላቅ ጠንቅቶች
lateral great

ቀዳማዊ ቲባይ ጠንቅቶች
anterior tibial

ረጅሚ ፊቡላይ ጠንቅቶች
long peroneal

ረጅሚ የእግር ጣቶች ዘርጊ ጠንቅቶች
long extensor of toes

አጭራ የእግር ጣቶች ዘርጊ ጠንቅቶች
short extensor of toes

ሜማይ መሃእጥንታት ጠንቅቶች
plantar interosseous

ክባብ አይን ጠንቅቶች
orbicular of eye

ፍርምቤ ወክላዴ ወጠታይ ጠንቅቶች
sternocleidomastoid

ጠረጴዛይ ጠንቅቶች
trapezius

ትልቅ የደረት ጠንቅቶች
greater pectoral

ክንዳይ ክልኤ-እራስ ጠንቅቶች
biceps of arm

ክንዳይ ጠንቅቶች
brachial

ክቦ ገልብጢ ጠንቅቶች
round pronator

ረጅሚ መዳፋይ ጠንቅቶች
long palmar

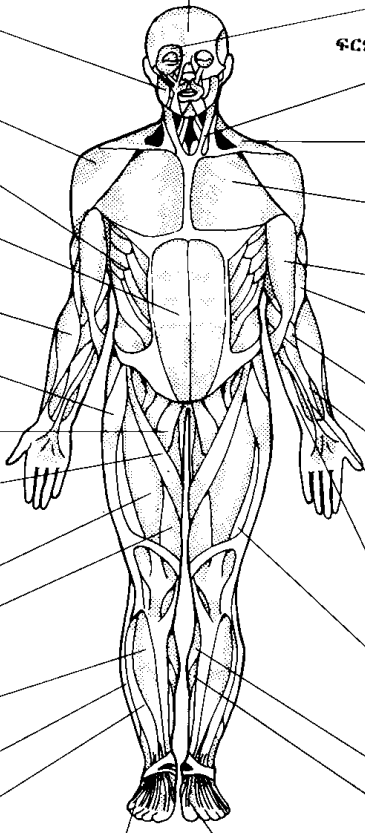
አጭራ መዳፋይ ጠንቅቶች
short palmar

ኡልናይ አምባር መዋያ አጣሬ ጠንቅቶች
ulnar flexor of wrist

መሃላይ ትላቅ ጠንቅቶች
medial great

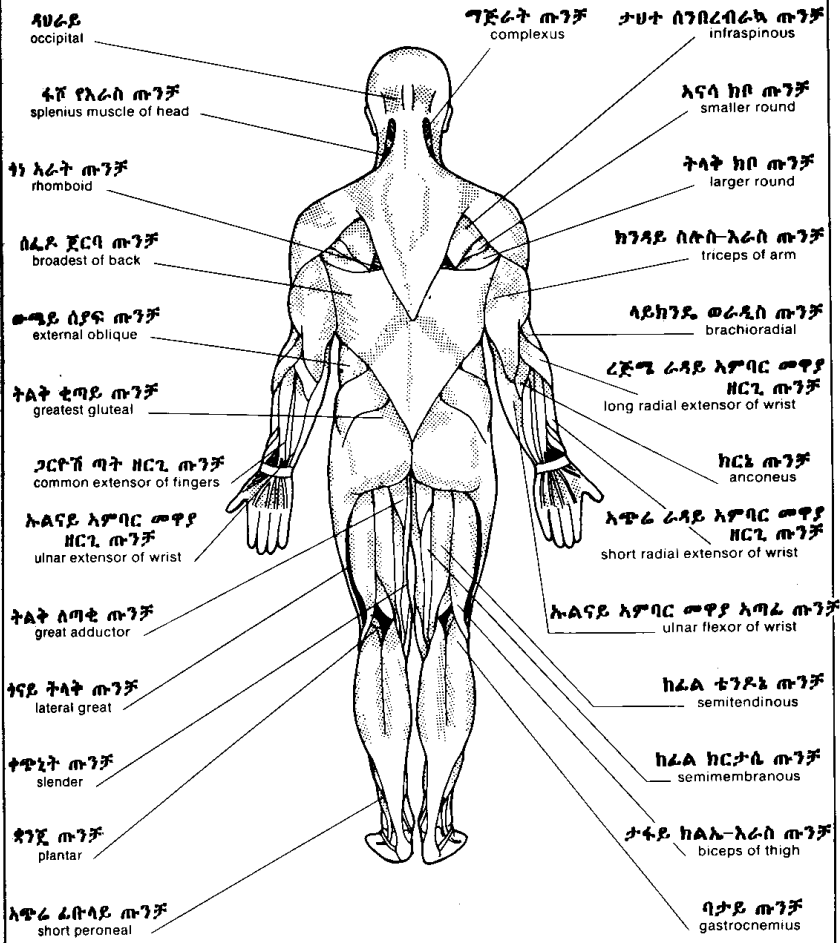
ባታይ ጠንቅቶች
gastrocnemius

ትልጥም ጠንቅቶች
soleus



ጡንቻዎች
muscles

የሀራይ ርእይ
posterior view



የሀራይ
occipital

ግጅራት ጡንቻ
complexus

ታህተ ስንብረብራካ ጡንቻ
infraspinous

ፋቮ የእራስ ጡንቻ
splenius muscle of head

እናሳ ክቦ ጡንቻ
smaller round

ከነ አራት ጡንቻ
rhomboid

ትላት ክቦ ጡንቻ
larger round

ሰፊ ደ ጀርባ ጡንቻ
broadest of back

ከንዳይ ስሎ-እራስ ጡንቻ
triceps of arm

ውጫይ ሰያፍ ጡንቻ
external oblique

የይክንዴ ወራዲስ ጡንቻ
brachioradial

ትልቅ ቴጣይ ጡንቻ
greatest gluteal

ረጅሜ ራዳይ አምባር ሙዋያ
ዘርጊ ጡንቻ
long radial extensor of wrist

ጋርቶሽ ጣት ዘርጊ ጡንቻ
common extensor of fingers

ክርኔ ጡንቻ
anconeus

ኩልናይ አምባር ሙዋያ
ዘርጊ ጡንቻ
ulnar extensor of wrist

አጭራ ራዳይ አምባር ሙዋያ
ዘርጊ ጡንቻ
short radial extensor of wrist

ትልቅ ሰጣቂ ጡንቻ
great adductor

ኩልናይ አምባር ሙዋያ አጣፊ ጡንቻ
ulnar flexor of wrist

ጎናይ ትላት ጡንቻ
lateral great

ከፊል ቴንዶኔ ጡንቻ
semitendinous

ቀጭኒት ጡንቻ
slender

ከፊል ክርታሴ ጡንቻ
semimembranous

ዳንጂ ጡንቻ
plantar

ታፋይ ክልኢ-እራስ ጡንቻ
biceps of thigh

አጭራ ፊቡላይ ጡንቻ
short peroneal

ባታይ ጡንቻ
gastrocnemius

አዕም
skeleton

ቀዳማዊ ርእይ
anterior view

ግንባራዊ
frontal

ጆሮግንዳይ
temporal

አጥመክሳድ
clavicle

ብራካ
scapula

ሁመር
humerus

ራዲስ
radius

ሁለፍ
ulna

አንባር አጥም
carpus

መዳፋጥም
metacarpus

ቲቢያ
tibia

አጥመ ቁርጭምጭሚት
tarsus

አጥመሚማ
metatarsus

ቀሪብ አዕመጣት
proximal phalanx

መሃል አዕመጣት
middle phalanx

ርሁት አዕመጣት
distal phalanx

ጉንጭ አጥንት
malar bone

ላይኛው ግንጭል
maxilla

ታችኛው ግንጭል
mandible

ፍርምባ
sternum

ጎድን
ribs

ሰጥር
floating rib

አከርካሪ
vertebral column

አኒሳ
ilium

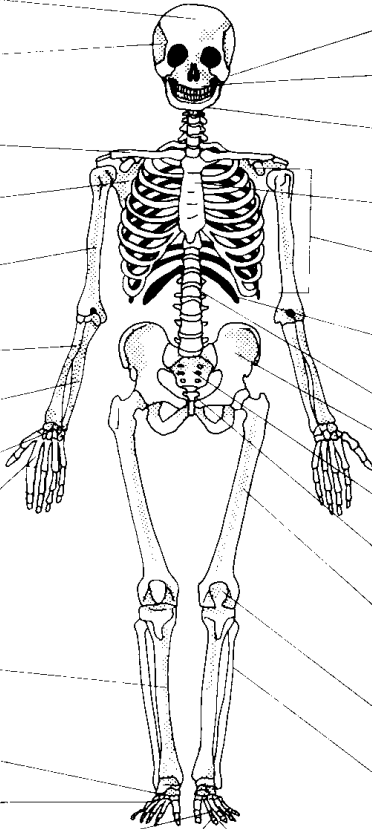
ጅባር
sacrum

ቅርጅራት
coccyx

ፊሙር
femur

ጉልበት ሎሚ
patella

ፊቡላ
fibula



አፅም
skeleton

ጸሀራይ ርእይ
posterior view

ግራናማይ
parietal

ጸሀራይ
occipital

ሰንበረ ብራኳ
spine of scapula

ጻለትሮክሌ
epitrochlea

ጻለ ኩርኩሚ
epicondyle

ከርንአፅም
olecranon

ጥሙጻን ጎድኖች
false rib (3)

እራሰፊሙር
head of femur

አንገተፊሙር
neck of femur

ትላቅ ጉጠአጥንት
greater trochanter

መንበሬ
ischium

ጎናይ ፊሙራይ ኩርኩሚ
lateral condyle of femur

መሃላይ ፊሙራይ ኩርኩሚ
medial condyle of femur

ዋልቶ አክርካሪ
atlas

ቅጥርቶ አክርካሪ
axis

አንገት አክርካሪ
cervical vertebra (7)

ቸላ ብራኳ
acromion

እራሰሁመር
head of humerus

ጋድማይ አካለአክርካሪ
transverse process of vertebra

አምቤ አክርካሪ
thoracic vertebra (12)

እሽሄ አካለአክርካሪ
spinous process of vertebra

ቀሪብ አፅመጣት
proximal phalanx

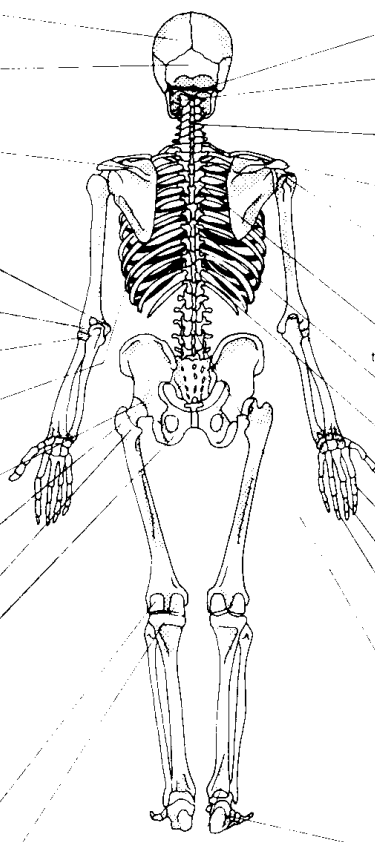
መሃል አፅመጣት
middle phalanx

ርሁቅ አፅመጣት
distal phalanx

ወገብ አክርካሪ
lumbar vertebra (5)

ልላ ተረከዝ
talus

አፅመተረከዝ
calcaneus



ሰን አጥንተ ራስቅል
osteology of skull

ጎናይ እይታ
lateral view

ቀዳማይ ርእይ
anterior view
ጉድጓድ ስርጉ
nasal fossa

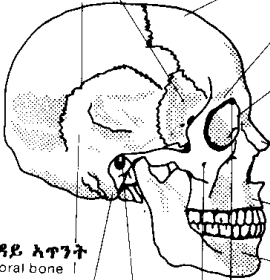
ሽብልቄ አጥንት
sphenoid bone

ግንባር አጥንት
frontal bone

እስካሞስ ሰፈት
squamous suture

ላላላሽፋሽፋት ቅስት
superciliary arch

ጉንጭ አጥንት
zygomatic bone



ጉድጓድ አይን
orbital cavity

ጆር ግንዳይ ስርጉድ
temporal fossa

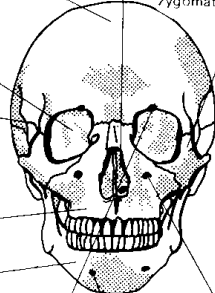
ስርጉእፅፍ
nasal bone

ላይኛው ግንጭል
maxilla

ታችኛው ግንጭል
mandible

ላላላ ጉድጓድ አይን ፋካ
supraorbital foramen

ጉንጭ አጥንት ፋካ
zygomaticofacial foramen



ታሀተጉድጓድ አይን ፋካ
infraorbital foramen

አገጫይ ፋካ
mental foramen

ጆር ግንዳይ አጥንት
temporal bone

ጠቶ አካል
mastoid process

ውጫይ ሰግታይ ዞይ
external auditory meatus

ላለላይ እይታ
superior view

ታሀተይ እይታ
inferior view

frontal bone

ጥንክሬ ላንቃ
hard palate

ግንባርን ሰፈት
metopic suture

ቀንበራይ ቅስት
zygomatic arch

ሞላሌ ፋካ
foramen ovale

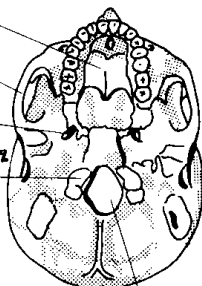
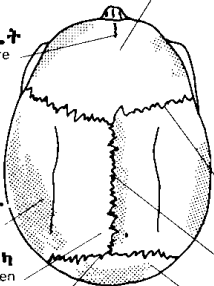
ዳሀራይ ራስ ቅል ኩርኩጫ
occipital condyle

አናታይ ሰፈት
coronal suture

ፍላግይ ሰፈት
sagittal suture

ዳሀራይ ራስ ቅል አጥንት
occipital bone

ትልቅ ፋካ
great foramen



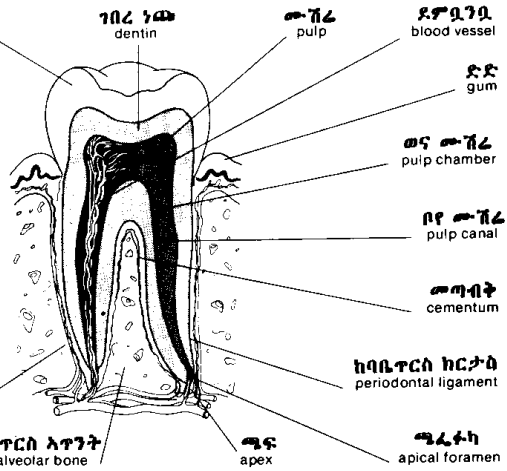
ግራናማይ አጥንት
parietal bone

ግራናማይ ፋካ
parietal foramen

ላምብድ ሰፈት
lambdoid suture

ጥርስ
teeth

መንጋጋ ፍላጭ
cross section of a molar

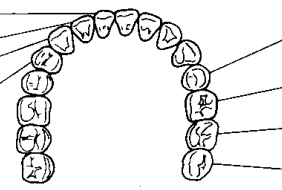


- ኃጩ enamel
- ገበረ ኃጩ dentin
- ሙሽረ pulp
- ደግሲንቧ blood vessel
- ደድ gum
- ወና ሙሽረ pulp chamber
- ቦየ ሙሽረ pulp canal
- ሙግብት cementum
- ከባቤጥርስ ከርታስ periodontal ligament
- ሙሰኬ ጥርስ dental alveolus
- ሙሰኬጥርስ አጥንት alveolar bone
- ጫፍ apex
- ጫረተካ apical foramen

- አናት crown
- አንገት neck
- ሰር root

ጥርሳተ ሰብሊ
human denture

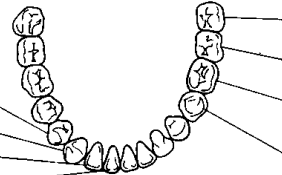
ላይኛው ገንጭላ
maxilla



- መሃላይ ፊትጥርስ central incisor
- ጎናይ ፊትጥርስ lateral incisor
- ክራንቻ canine
- አንደኛ ቀዲፎ መንጋጋ first premolar
- አንደኛ ቀዲፎ መንጋጋ first premolar
- ክራንቻ canine
- ጎናይ ፊት ጥርስ lateral incisor
- መሃላይ ፊት ጥርስ central incisor

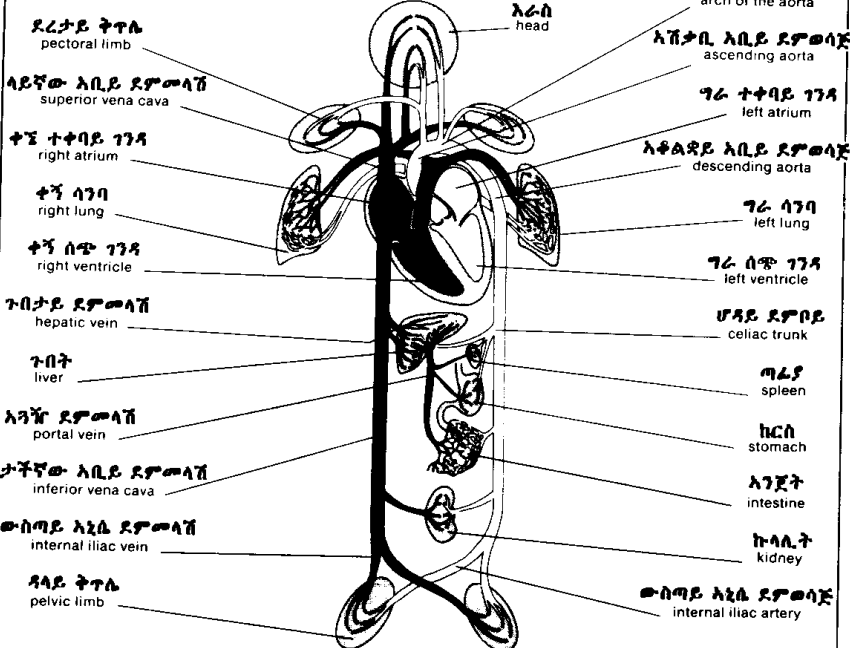
- ሁለተኛ ቀዲፎ መንጋጋ second premolar
- አንደኛ መንጋጋ first molar
- ሁለተኛ መንጋጋ second molar
- ሶስተኛ መንጋጋ third molar
- ሶስተኛ መንጋጋ third molar
- ሁለተኛ መንጋጋ second molar
- አንደኛ መንጋጋ first molar
- ሁለተኛ ቀዲፎ መንጋጋ second premolar

ታችኛው ገንጭላ
mandible

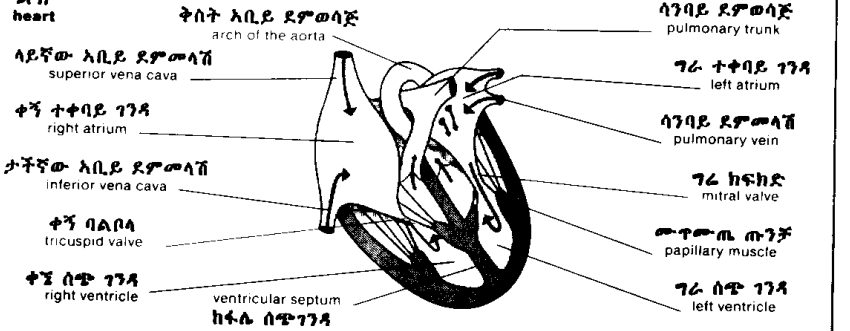


ዘውረ ደፍ
blood circulation

ዘውረ ደፍ ገፅታ
schema of circulation



ልብ
heart



ዘውረ ደም

blood circulation

ዋና ዋናዎች ደምመላሾችና ደምወሳጆች
principal veins and arteries

ውስጣዊ የጉርር ደምመላሽ
internal jugular vein

ጋርቶሽ የአንጎል ደምወሳጅ
common carotid artery

ታህተክሳድ ደምመላሽ
subclavian vein

ታህተክሳድ ደምወሳጅ
subclavian artery

ላይኛው አቢይ ደምመላሽ
superior vena cava

ብብታይ ደምወሳጅ
axillary artery

ሳንባይ ደምመላሽ
pulmonary vein

ከንዳይ ደምወሳጅ
brachial artery

ታችኛው አቢይ ደምመላሽ
inferior vena cava

ጉበታይ ደምመላሽ
hepatic vein

አጎሹ ደምመላሽ
portal vein

ራዲያዊ ደምወሳጅ
radial artery

ኡልና ደምወሳጅ
ulnar artery

ቀዳም አንጀታይ ደምወሳጅ
superior mesenteric artery

ጋርቶሽ አኒሴ ደምወሳጅ
common iliac artery

ውስጣዊ አኒሴ ደምወሳጅ
internal iliac artery

ውጫይ አኒሴ ደምወሳጅ
external iliac artery

ሳንባይ ደምወሳጅ
pulmonary artery

ብብታይ ደምመላሽ
axillary vein

ጋርቶሽ ጉበታይ ደምወሳጅ
common hepatic artery

አራስ አቅጣ ደምመላሽ
cephalic vein

አንጋፋ ደምመላሽ
basilic vein

ጣፋይ ደምወሳጅ
splenic artery

ጣፋይ ደምመላሽ
splenic vein

ታችከንዶ ደምመላሽ
cubital vein

ራዲስ ደምመላሽ
radial vein

ኩላሊታይ ደምወሳጅ
renal artery

ኩላሊታይ ደምመላሽ
renal vein

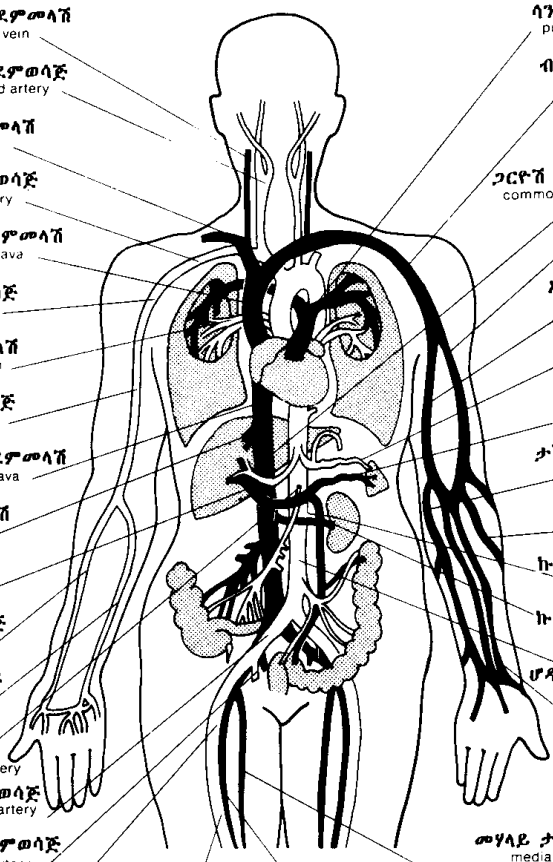
ሆዳይ አቢይ ደምወሳጅ
abdominal aorta

መሃላይ ታችከንዶ ደምመላሽ
median vein of forearm

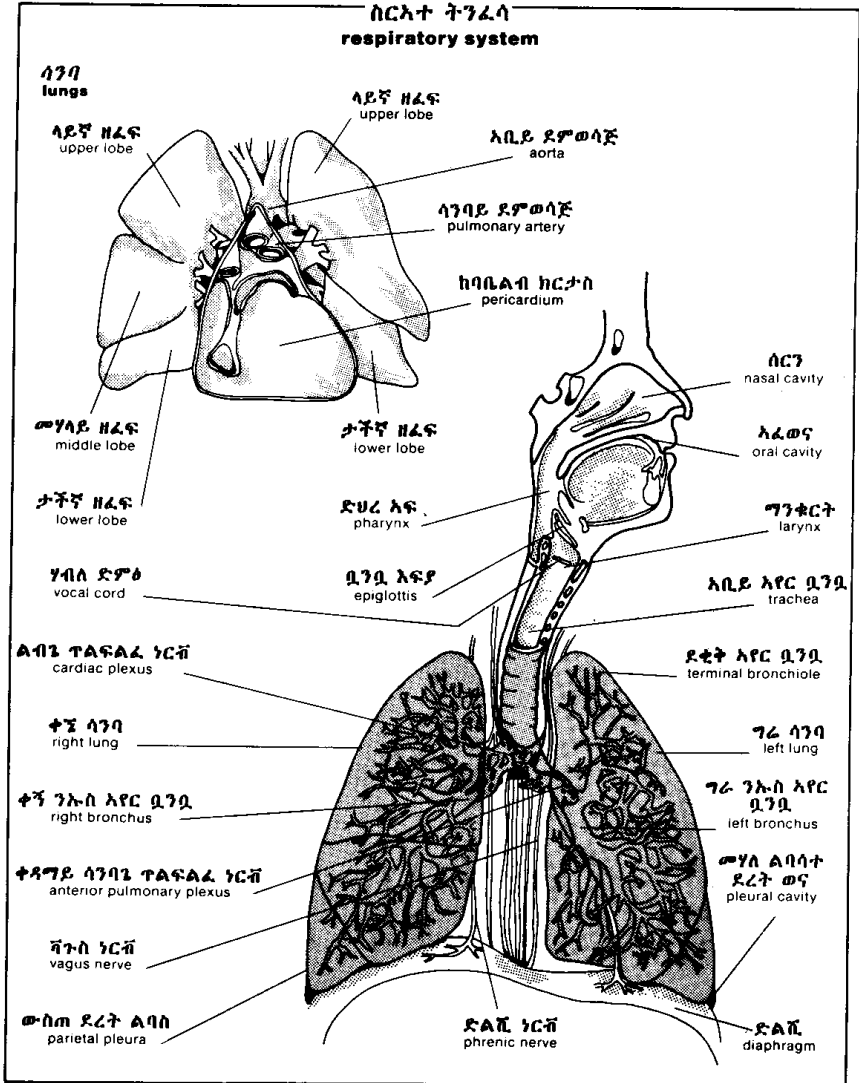
ፊሙራ ደምወሳጅ
femoral artery

ፊሙራ ደምመላሽ
femoral vein

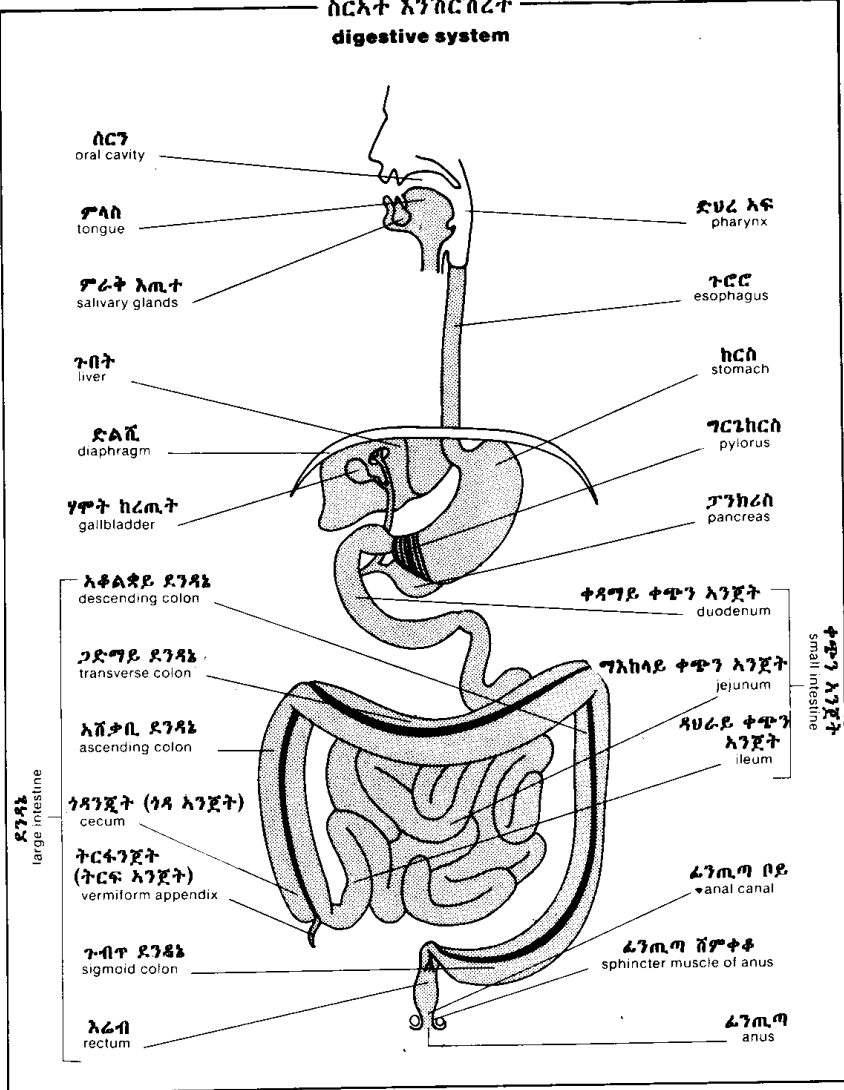
አቢይ ግልጤ ደምመላሽ
great saphenous vein



ሰርአተ ትንፈሳ
respiratory system



ሰርአተ እንሽርሽረት
digestive system



ሰርጉ
oral cavity

ፖላስ
tongue

ፖራት እጢተ
salivary glands

ጉብት
liver

ድልቪ
diaphragm

ሃሞት ከረጢት
gallbladder

አቆልጃይ ደንዳኔ
descending colon

ጋድማይ ደንዳኔ
transverse colon

አሸቃቢ ደንዳኔ
ascending colon

ጎዳንጀት (ጎዳ አንጀት)
cecum

ትርፋንጀት
(ትርፍ አንጀት)
vermiform appendix

ጉብጥ ደንዳኔ
sigmoid colon

እራብ
rectum

ድሀረ አፍ
pharynx

ጉሮሮ
esophagus

ከርስ
stomach

ግርኒከርስ
pylorus

ፓንክሪስ
pancreas

ቀዳማይ ቀጭን አንጀት
duodenum

ግእከላይ ቀጭን አንጀት
jejunum

ዳሀራይ ቀጭን
አንጀት
ileum

ቀጭን አንጀት
small intestine

ፊንጢን ቦይ
anal canal

ፊንጢን ሸምቀቆ
sphincter muscle of anus

ፊንጢን
anus

ደንዳኔ
large intestine

ሰርአተ ሸኚ
urinary system

ታችኛው አቢይ ደምመላሽ
inferior vena cava

ኩላሊት ላይኛው ግራንድ
suprarenal gland

ቀኛ ኩላሊት ፍላጭ አካል
right kidney (sagittal section)

ውሀ ኩላሊት
cortex

ውስጠ ኩላሊት
medulla

ኩላሊት ቤሃ
calyx

ኩሊንግዳ
pelvis

ኩላሊት ገሳ
renal papilla

ማልፒጂ ፒራሚድ
Malpighi's pyramid

ፊኛ ቦይ
ureter

ጋርዮሽ አኒሲ ደምመላሽ
common iliac artery

ጋርዮሽ አኒሲ ደምመላሽ
common iliac vein

ፊኛ
urinary bladder

ሆላይ ደምቦይ
celiac trunk

ግራ ኩላሊት
left kidney

ኩላሊት ደምወሳጅ
renal artery

ኩሊት ለምብርት
hilus of kidney

ኩላሊት ደምመላሽ
renal vein

ኩላሊት ወና
sinus of kidney

ቀዳም አንጀታይ ደምወሳጅ
superior mesenteric artery

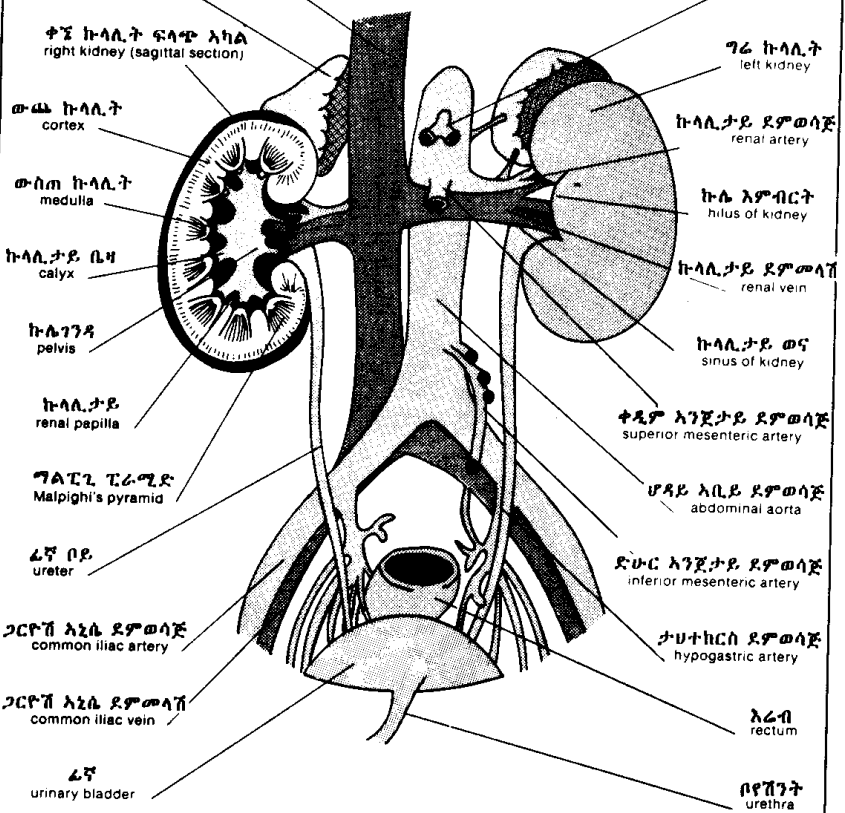
ሆላይ አቢይ ደምወሳጅ
abdominal aorta

ድቡር አንጀታይ ደምወሳጅ
inferior mesenteric artery

ታሁተኩርሰ ደምወሳጅ
hypogastric artery

አራብ
rectum

ቦይሽንት
urethra



ሰርአተ ነርቭ nervous system

ዘርፋይ ሰርአተ ነርቭ peripheral nervous system

አገገላ በተላ ነርቮች cranial nerves

አገገታይ ጥላፍላፍ cervical plexus

ከገዳይ ጥላፍላፍ brachial plexus

ላላላ ብራካ ነርቭ suprascapular nerve

ጡንቻውቀዳ ነርቭ musculocutaneous nerve

ብብታይ ነርቭ axillary nerve

ጎድናተመሃላ ነርቭ intercostal nerve

አኒሳ ወታይተከርስ ነርቭ iliohypogastric nerve

ነርቭ ራዲስ radial nerve

አኒሳ ወጡራዳ ቆለጥ ነርቭ ilioinguinal nerve

ኡላይ ነርቭ ulnar nerve

ፈጠራ ነርቭ femoral nerve

ወገባይ ጥላፍላፍ lumbar plexus

ቴጣይ ነርቭ gluteal nerve

መሃይ ነርቭ median nerve

ጣታይ ነርቭ digital nerve

ጅብራይ ጥላፍላፍ sacral plexus

ቅሪጅራት ነርቭ coccygeal nerve

ጎናይ ቋንቋዳ ነርቭ lateral cutaneous nerve of thigh

ዳሀራይ ቋንቋዳ ነርቭ posterior cutaneous nerve of thigh

መንበረ ነርቭ sciatic nerve

አግደ ነርቭ obturator nerve

ጋርዮቭ ፈቡሌ ነርቭ common peroneal nerve

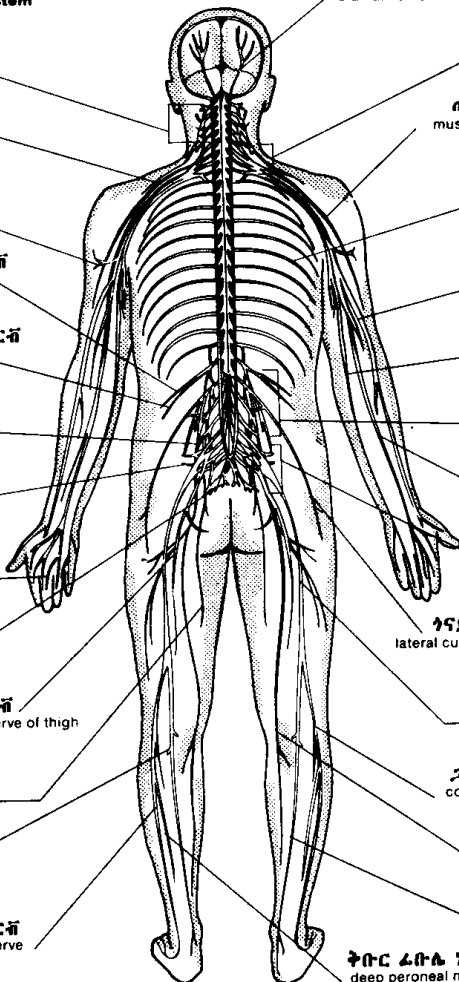
ባታይ ነርቭ sural nerve

ገላጤ ነርቭ saphenous nerve

አቅቡር ፈቡሌ ነርቭ superficial peroneal nerve

ቴባይ ነርቭ tibial nerve

ቅቡር ፈቡሌ ነርቭ deep peroneal nerve



ሰርአተ ነርቭ
nervous system

ግእከላዊ ሰርአተ ነርቭ
central nervous system
cerebrospinal axis (sagittal section)
እንጎልወሰረሰር ፍላጭ

ላይኛ ጋድግዬ ወና
superior longitudinal sinus

ገጫሳተ አንጎል አያያኝ
corpus callosum

አቢይ እንጎል
cerebrum

ትርሽጫ እካል
pineal body

ብፋሀ ከፋሊ
septum lucidum

ዳሀራይ መጋጥም
posterior commissure

ቀዳግይ መጋጥም
anterior commissure

ንኡስ እንጎል
cerebellum

እይታይ መስቀል
optic chiasm

ሰረሰርጌ እንጎል
medulla oblongata

ፒቱ ሊጢ
pituitary gland

ውጫይ ልባስ ሰረሰር
dura mater
of spinal cord

ቫርሊ ድልድይ
pons Varolii

ሰረሰር
spinal cord

የወገባይ አከርካሪ ገፅታ
medullar axis of lumbar vertebra

አገናኝ ቅርንጫፈ ነርቭ
communicating rami

አከርካሪ ፋካ
intervertebral foramen

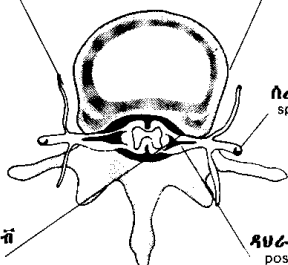
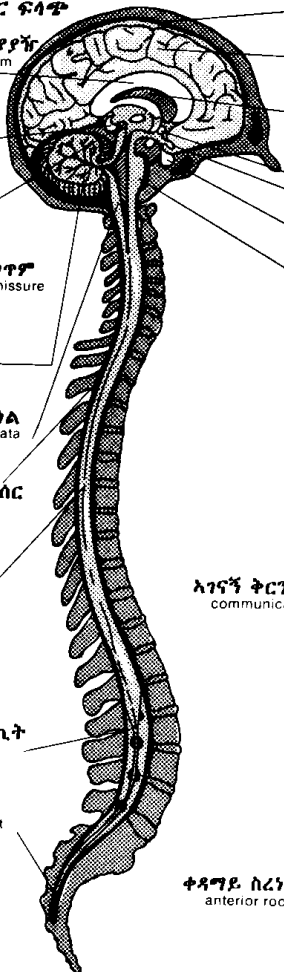
ልባስ ሰረሰር ክረጢት
dural cul-de-sac

ጫሊ ሰረሰር
terminal filament

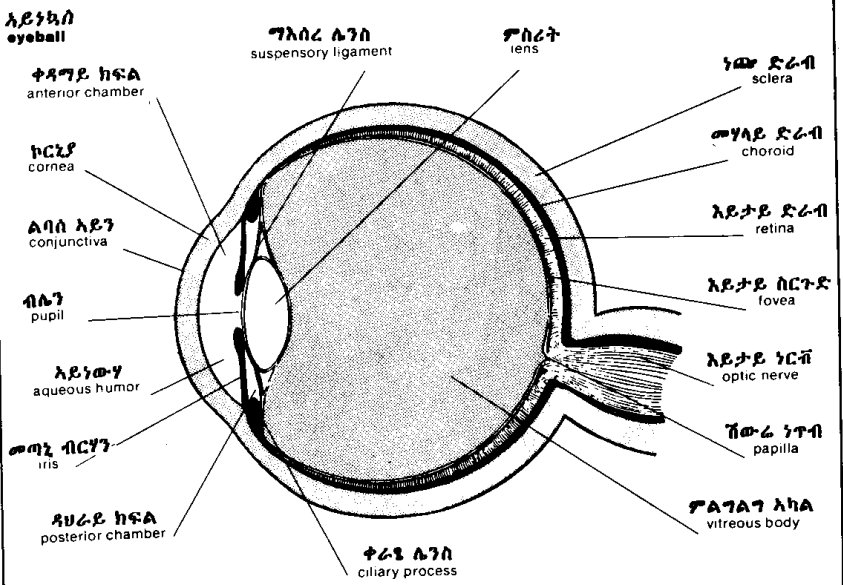
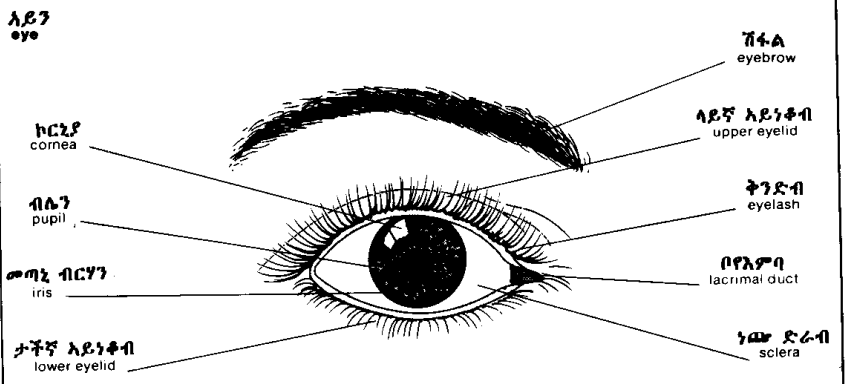
ሰረሰር ነርቭ
spinal nerve

ቀዳግይ ስረነርቭ
anterior root

ዳሀራይ ስረነርቭ
posterior root



አባባተ ስሜት እይታ
sense organs : sight



አባላት ስሜት ስሜ
sense organs: hearing

ውጫይ ጆር
external ear

ስሱስ ግእዘኔ ስርተድ
triangular fossa

አጎርባቤ
antihelix

ዛጎሌ
concha

አጉጢት
antitragus

ጎርባቤ ዋራ
tail of helix

ለዎለዎ ጆር
lobule

ጎርባቤ
helix

አግረ ጎርባቤ
crus of helix

ቀዳግይ ስላች
anterior notch

ጉጢት
tragus

ውጫይ ስሜ ስይ
external acoustic meatus

መሃለ ጉጢቶች ስላች
intertragic notch

ውስጣይና መሃላይ ጆር
internal and middle ear

ውጫይ ጆር
external ear

መሃላይ ጆር
middle ear

ውስጣይ ጆር
internal ear

አፅግተ ስሜ
auditory ossicles

ጆር ታዎቡር
ear drum

ቆርቦተ ጆር
auricle

ውጫይ ስሜ ስይ
external acoustic meatus

ጎናይ ንፍቀክብ ስይ
lateral semicircular canal

ታችኛ ንፍቀክብ ስይ
posterior semicircular canal

ላይኛ ንፍቀክብ ስይ
superior semicircular canal

ነርቭ ሙዳርቭ ስይ
vestibular nerve

ፈታይ ነርቭ
facial nerve

ነርቭ ጥምዚ
cochlear nerve

ሙዳርቭ ስይ
vestibule

ጥምዚ
cochlea

ኡስታች ስይ
Eustachian tube

አባለተ ሰሜት ሽታ
sense organs: smell

ውጫይ አፍንጫ
external nose
ሰርው-አፍንጫ
root of nose

ለላለ አፍንጫ
dorsum of nose

ጉርጉይ ሰርን
nasal fossae

ወንፊቲ አጥንት
cribriform plate of ethmoid

አፍንጫ ቀዳዳ
naris

አፍንጫ ጫፍ
tip of nose

ላይኛ ሽብል አጥንት
superior nasal concha

መካካይ ሽብል አጥንት
middle nasal concha

ታችኛ ሽብል አጥንት
inferior nasal concha

አፍንጫ ክንፍ
ala

AA ከፋሊ አፍንጫ
mobile septum of nose

ወና ሽብል ቅት
sphenoidal sinus

ኡስታች ቦይ
Eustachian tube

ከንፈር ቦይ
philtrum

ገንባራይ ወና
frontal sinus

ሰርን አፅም
nasal bone

አቢይ ከንፈአፍንጫ
greater alar cartilage

ላይኛው ገንጥል
maxilla

ሰርኛ ድሀረአኛ
nasopharynx

ሰሜተ ሽታወጣእም
senses of smell and taste

ሽታይ ኩርት
olfactory bulb

ብሩን ክርታስ
Brunn's membrane

ሽታይ አንጎል
rhinencephalon

ሽታይ ክርታስ
olfactory membrane

ጥላስ
tongue

ሽታይ ነርቭ
olfactory nerve

አንጥል
uvula

ላገታ
palate

አፍንጫ ግ ከፋሊ ለግፅም
septal cartilage of nose

አባላት ስሜት ጣእም
sense organs : taste

አፍ
mouth

ጥንክረ ላንቃ
hard palate

እንጥል
uvula

ወጋጥመ ከንገር
commisure of lips of mouth

ጥቡስ ጉሮሮ
isthmus of fauces

ፖላስ
tongue

ታችኛ ቅስት ጥርስ
inferior dental arch

ላይ ከንገር
upper lip

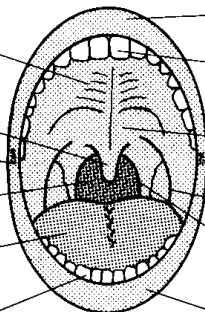
ላይኛ ቅስት ጥርስ
superior dental arch

ገረ ላንቃ
soft palate

ላንቃ ፖላሳይ ቅስት
palatoglossal arch

ላንቃ ድሀረአፍ ቅስት
palatopharyngeal arch

ታች ከንገር
lower lip



ለእለ ፖላስ
dorsum of tongue

ስርወ ፖላስ
root

ላካል
body

ግፍ
apex

ባልኛ ድርድር
V-shaped row

ቧንቧ እፍፍ
epiglottis

ፖላሳይ ተንሲል
lingual tonsil

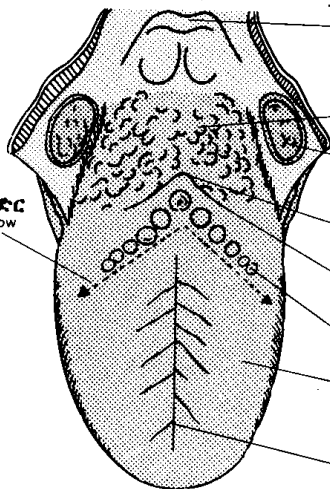
ላንቃይ ተንሲል
palatine tonsil

ፖላሳይ ፉካ
foramen cecum

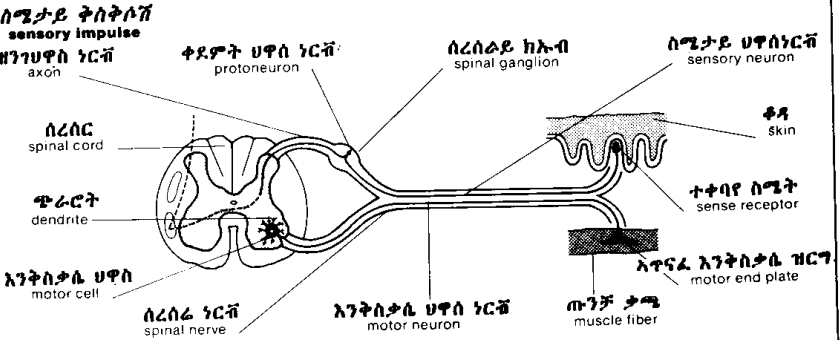
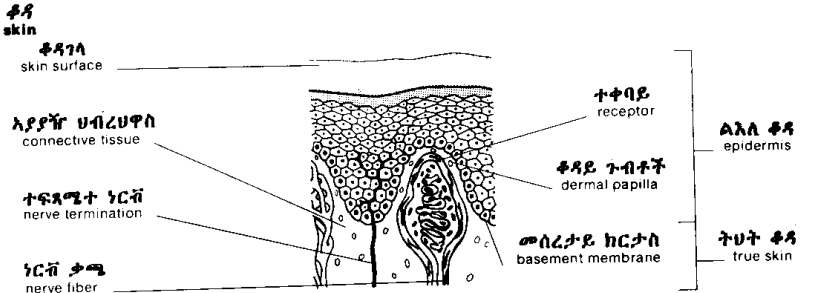
ጥንገ ፖላስ ቦይ
sulcus terminalis

ፖላሳይ ጉብታዎች
lingual papillae

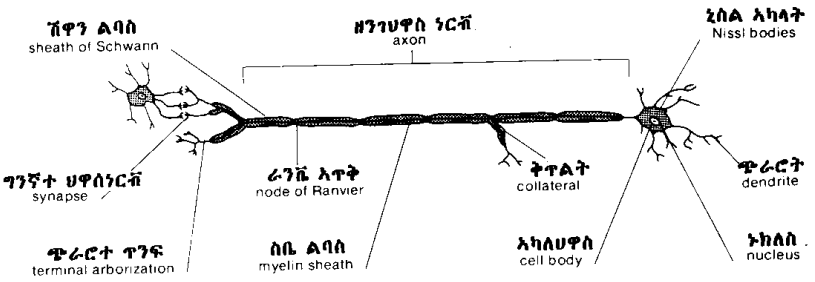
መሃላይ ቦየፖላስ
median lingual sulcus



አባላት ስሜት ነኪ
sense organs : touch



ህዋስ ነርቭ
neuron



ጥፍር
nail

አልተጣብቄ ጠርዘጥፍር
free margin

ጠረቂት
lunula

ረሳግ
cuticle

ላላ ጥፍር
eponychium

ጠረቂት
lunula

አካል ጥፍር
body of nail

አልተጣብቄ ጠርዘጥፍር
free margin

ሶል
sole

ጥፍር መደብ
nail bed

ላላ ቀዳ
epidermis

ሰርፀ ጥፍር
nail matrix

ሰረ ጥፍር
root of nail

ትህት ቀዳ
dermis

አሻራ
digital pulp

ርሀት አፅመጣት
distal phalanx

ፀጉር
hair

ላላ ቀዳ
epidermis

አፍአ
ostium

ዘገገ ፀጉር
hair shaft

ትህት ቀዳ
dermis

ውጫይ አፎተሰር
outer root sheath

ውስጣይ አፎተሰር
inner root sheath

ፀጉር ገትሬ ጡንቻ
muscle arrector pili

ፀጉራ ኩርት
hair bulb

ሽውራ ነጥብ
papilla

ደፍ ቧንቧ
blood vessel

ነርቭ
nerve

hair follicle
ጉድጓዶ ፀጉር

ዘገገ ፀጉር
hair shaft

ወዝ አጤ
sebaceous gland

ቀዳየ ፀጉር
epidermicula

ውጫ ፀጉር
cortex

ውስጠ ፀጉር
medulla

ሰረ ፀጉር
root of hair

አለቶ ሀዋሳት
indifferent cells