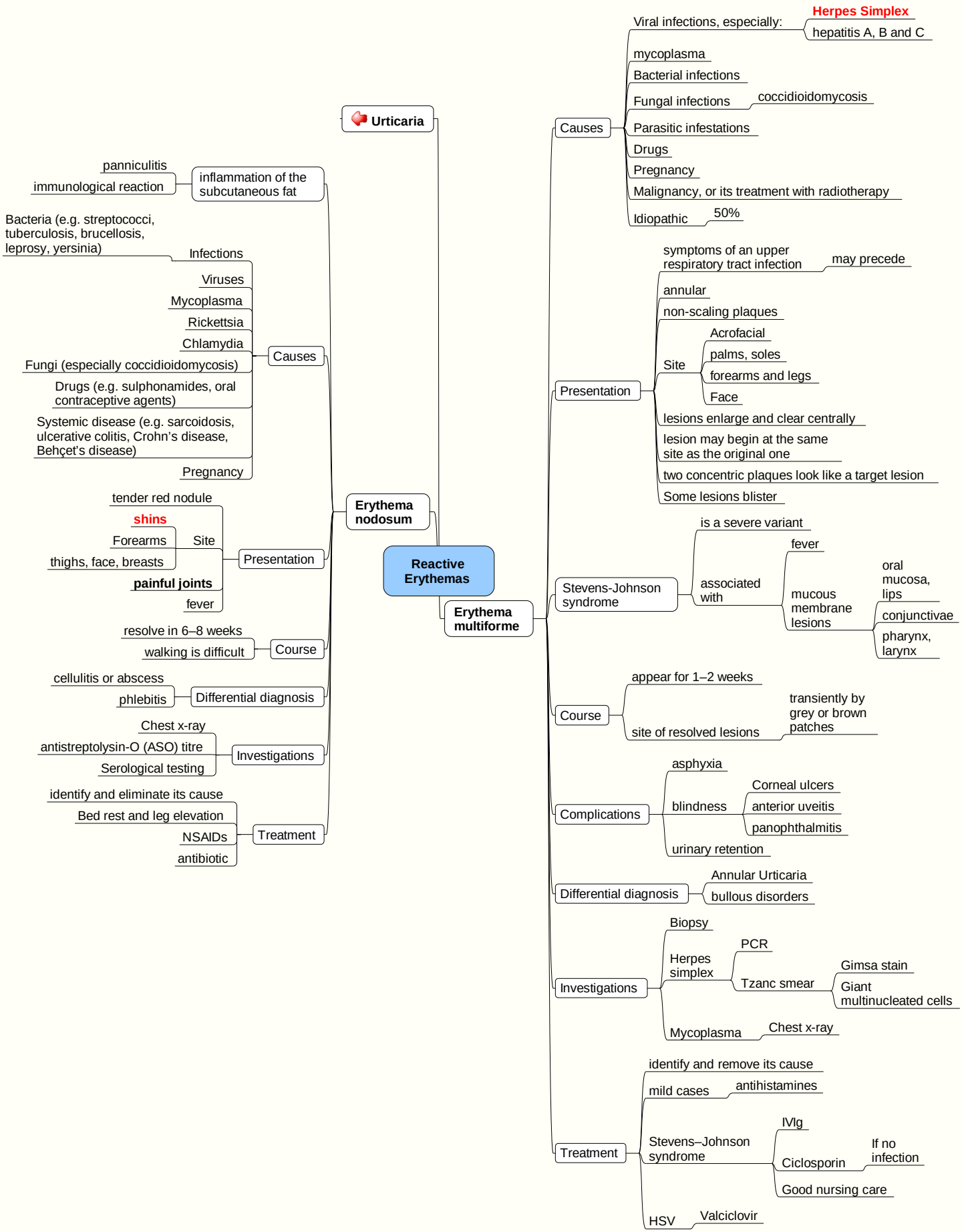
Reactive Erythemas
Urticaria
Erythema nodosum
inflammation of the subcutaneous fat
panniculitis
immunological reaction
Causes
Infections
Bacteria (e.g. streptococci, tuberculosis, brucellosis, leprosy, yersinia)
Viruses
Mycoplasma
Rickettsia
Chlamydia
Fungi (especially coccidioidomycosis)
Drugs (e.g. sulphonamides, oral contraceptive agents)
Systemic disease (e.g. sarcoidosis, ulcerative colitis, Crohn's disease, Behçet's disease)
Pregnancy
Presentation
tender red nodule
Site
shins
Forearms
thighs, face, breasts
painful joints
fever
Course
resolve in 6–8 weeks
walking is difficult
Differential diagnosis
cellulitis or abscess
phlebitis
Investigations
Chest x-ray
antistreptolysin-O (ASO) titre
Serological testing
Treatment
identify and eliminate its cause
Bed rest and leg elevation
NSAIDs
antibiotic
Erythema multiforme
Causes
Viral infections, especially:
Herpes Simplex
hepatitis A, B and C
mycoplasma
Bacterial infections
Fungal infections
coccidioidomycosis
Parasitic infestations
Drugs
Pregnancy
Malignancy, or its treatment with radiotherapy
Idiopathic
50%
Presentation
symptoms of an upper respiratory tract infection
may precede
annular
non-scaling plaques
Site
Acrofacial
palms, soles
forearms and legs
Face
lesions enlarge and clear centrally
lesion may begin at the same site as the original one
two concentric plaques look like a target lesion
Some lesions blister
Stevens-Johnson syndrome
is a severe variant
associated with
fever
mucous membrane lesions
oral mucosa, lips
conjunctivae
pharynx, larynx
Course
appear for 1–2 weeks
site of resolved lesions
transiently by grey or brown patches
Complications
asphyxia
blindness
Corneal ulcers
anterior uveitis
panophthalmitis
urinary retention
Differential diagnosis
Annular Urticaria
bullous disorders
Investigations
Biopsy
Herpes simplex
PCR
Tzanc smear
Gimsa stain
Giant multinucleated cells
Mycoplasma
Chest x-ray
Treatment
identify and remove its cause
mild cases
antihistamines
Stevens–Johnson syndrome
IVIg
Ciclosporin
If no infection
Good nursing care
HSV
Valciclovir